

From the Orthopaedic Clinic of the Medical Academy
"Carl Gustav Carus"
Dresden
Chief physician: Dr. med.
Johannes Büschelberger

Studies on the peculiarities of the hip joint in infancy and their role in pathogenesis,
prophylaxis and the treatment of hip luxation

Postdoctoral lecture qualification paper
to obtain the degree of a qualified professor doctor in medicine

submitted
to the high senate of the Medical Academy "Carl Gustav Carus"
in Dresden

under the rectorship of the professor with the chair for pharmacology Dr. med. qualified
prof. Oelßner

from
Dr. med. Johannes Büschelberger
from Dresden

1 9 6 1

Table of contents

	Page
Introduction	
Terminology and views about the causes of hip luxation	3
Problem	4
The human hip joint in anthropological research	4
The human infant as a "secondary next resider" and "physiological premature infant"	7
The maturation of the extremities	9
The physiological reduced extension of the infant hip joint, its causes and its meaning in the pathogenesis of hip luxation	15
The abduction inhibition of the hip joint	27
Postnatal condition and development of the acetabulum	29
The X-ray examination of the infant pelvis	35
The functional and mechanical significance of the physiological reduced extension of the hip joint and the "circuitous development" of the hip joint body	40
The application of the theory of PAUWELS regarding the differentiation of the supporting tissues on the formation of deformities with hip luxation	47
Clinical signs of the dysplastic hip joint and its relationships with metabolic disorders	49
The physiological and pathological hypertension of the muscles as a pathogenic factor of hip luxation	51
Hip luxation and traditional customs	55
Conclusions for prophylaxis and the treatment of hip luxation	61
Summary	64
Literature	66
Photo credit	72

Introduction

Terminology and views about the causes of hip luxation

The congenital hip luxation (LH) has been increasingly of medical interest for about 200 years. According to BERNBECK, "congenital hip luxation" is to be understood both as the so-called hereditary hip joint dislocation (*luxatio coxae congenita*) as well as hip dysplasia (*dysplasia coxae congenita*) in all of its degrees, "because the dislocation of the femoral head from the socket is only a secondary symptom in the complex of this disease" (BERNBECK).

The views on the aetiology of LH have changed many times. Dreams that concern the womb (HIPPOCRATES) or intra partum act on the child (PETIT) were considered as causes of LH in earlier centuries. Soon, however, after people began to take a closer look at this deformity, the opinions changed. In addition to the local diseases, mainly exogenous and endogenous, intrauterine and extrauterine factors were made responsible for the occurrence of LH, a scientific controversy that has not yet been decided upon. However, SCHLEGEL believes that "today an approximation of both camps has been achieved".

LE DAMANY came up with his own theory in the year 1908. Starting from an anthropological hierarchy on which the white race is at the upper end where the LH is most frequently observed, and in connection with the development of the volumetric development of the brain, he concludes, as GAUGELE writes: "that the hip created quadruped has not yet been fully adapted for the upright gait of man. Above all, the upper human edge of the socket has developed too weakly and therefore does not offer enough support for the head during an upright gait".

After examining his employee VON HAYEK, VON LANZ came to a result of a very similar meaning. According to this, "the inclination of the socket inlet plane appears as a function of two organising principles. The one organising principle refers to the question of how far anteriorly or posteriorly the joint is displaced on the pelvic ring", the second refers to the form of the pelvic ring. "In such a comparative anatomical approach, the human acetabular roof appears phylogenetically young. It represents a new acquisition of the organism caused by the completed erection of the human body.

Because the structural form of the human acetabular roof in vertebrates was not anchored early enough and as a result, phylogenetically speaking, did not have enough time to mature, its biological connections are far from complete. Its important features are missing, as we repeatedly amazingly have to find on old mature structures". (VON LANZ) VON LANZ comes to the following conclusion considering the design and position change of the coxal femur end and acetabulum set just before birth and referred to by NAUCK as "circuitous development". "The structural form of the human hip joint represents a phylogenetically new acquisition, namely with respect to its acetabular roof. Its rough new development can all too easily exceed the biological and mechanical safety coefficients. The acetabular roof has not yet been completely secured".

Problem

Almost all examinations made in connection with LH refer to the upright gait of humans and therefore the tasks of the hip joint body, not only for the purpose of movement, but also to exert a load-bearing function. This requirement is clearly expressed in the cited statements of GAUGELE and VON LANZ, but also with many other authors. The functional significance that the hip joints have in ambulatory small children and adults therefore of course is also ascribed to the hip joints of newborns and infants.

The task of this paper is to investigate whether the hip joints of children in the 1st year of life can be equated to those of older children and adults in a functional respect, under which conditions postnatal pathological changes to the hip joints may occur in the sense of LH and how their prevention can be sought.

The following serve as the basis and path for a possible solution to this task:

paleoanthropological research results regarding walking upright,

the anthropological and biological studies by PORTMANN regarding "nest residents" and "nest leavers",

Notes on the maturation of the extremities with respect to the birth condition of humans as a "physiological prematurity",

anatomical, mechanical joint and radiographic examinations of hip joints of newborns,

the theory of PAUWELS regarding the influence of mechanical stimuli on the differentiation of the supporting tissue as well as

ethnographic observations and considerations on the problem of the "secondary nest resident".

Then the consequences should be drawn from the results obtained, which result for the care and treatment of infants to avoid LH.

The human hip joint in anthropological research

Many biologists correlate the incarnation with the abandonment of the quadruped gait and the appropriation of the biped gait, i.e. with the erection of the trunk. Our knowledge of the creation of real human types is still quite low and does not reach far enough back into past eras.

It is often concluded that walking upright is a still recent achievement of man for which the body has still not been able to form sufficient safeguards. For this reason, derailments of a disease nature would be easier than with "old mature structures" (VON LANZ). In

this context, abnormal changes are above all seen on the spine and hip joints, of which only the latter is of interest here.

With such a consideration, the question inevitably arises as to whether paleoanthropological research has information about at what age of the earth anthropoids and hominids began walking upright.

Even if we do not know anything precise about the time span that is necessary for a mechanical structure, such as the hip joint, to "mature", certain conclusions from known well-functioning and safe-functioning organ changes in humans and animals can indeed be made. If, for example, the skull of the pithecanthropus stage is compared with today's skull shapes, then we can clearly see that a time period of 200,000 to 600,000 years suffices for a very considerable shape change with mature structures to be completed.

In 1924 and later, numerous skeletal remains of pithecoïdal creatures (australopithecines) were found in Transvaal (South Africa) whose pelvis, in addition to the formation of the hands, are almost human in form so that the Australopithecus is accorded an upright gait.

The Australopithecus lived at the end of the tertiary period, so about one million years ago. Since the findings come from a period that ranges over a million years, the age of individual skeleton parts has to be estimated at approximately two million years, i.e. that there were already creatures of humanoid form with an upright gait over two million years ago.

The oldest evidence of the upright gait is the Oreopithecus found in Tuscany, which is a humanoid upright walking creature the size of the chimpanzee, which lived 10 to 12 million years ago (PORTMANN).

We do not know for sure whether the Oreopithecus is attributable to hominoids with their evolution to Homo sapiens or to anthropoids with the animal development or whether it is a common precursor to both groups. The opinions about the time of separation of the two directions of development differ from each other greatly, but "there is no reason to assume the separation of both pedigrees before the early Pliocene (last tertiary form 8 to 1 million years ago)" (GAFFREY). For the australopithecines, who lived at the end of the lignite time, a classification with the hominids is, however, justified, which is why HEBERER suggested that the australopithecines are better identified as prehomínids.

It is therefore to be noted that walking upright has been a terrestrial characteristic of prehistoric man and pithecanthropus (prehominids) and their descendants for at least two million years. Two million years may be regarded as a sufficient span of time for the "maturation of the structure" for the ball joint if you compare what enormous changes the brain underwent in the same period with its complex structure and moreover as a central controlling organ.

H. WEINERT writes very generally about the development of primates to which man belongs: "We will not be able to decide whether they had 30 or 60 million years to date for their development. It is also entirely irrelevant. It suffices to know that the duration of the generations is completely sufficient for ensuring all transformations from the most primitive prosimians to the most highly developed Homo sapiens".

The conclusion that VON LANZ draws from his anatomical examinations of the hip joint that the shape of the human hip joint is a phylogenetically new acquisition cannot be accepted due to the paleoanthropological research results.

For another reason, it cannot be accepted that the upright walking of man and therefore the shape and function of man's hip joint is still relatively young: In general, biologists and anthropologists previously were of the opinion that primitive man's posture became erect as a result of progressive brain development. The evolution of the posture is an effect of the volumetric increase of the brain, especially the cerebrum. The latest work by EDINGER, PORTMANN and others has, however, brought about the certainty that the higher cerebralisation must have always preceded the transformation of the ontogenesis type in the evolution of the group" (PORTMANN). "The humanoid differentiation of the hominids, especially the step to an upright posture", therefore occurred before the start of higher development of the human brain to today's form (PORTMANN).

The skull capacity of the roughly 12 cm large australopithecines is 500 to 700 ml and is therefore about 40% higher than that of today's living chimpanzees (500 ml). If one wants to draw the conclusion that the volumetric increase of the brain in the Australopithecus was already underway, then it must also be concluded that the acquisition of the upright posture is to be assigned to an even earlier time more than 2 million years ago. PORTMANN also states: "Walking upright was already realised before the formation of the later human brain".

From KLAATSCH it is doubted in the first place that man evolved from quadrupeds: "It should even be clear now that the earlier quite common consideration of man as the last link of a supposedly arduous development is not accurate. Man is not to be considered as the last result of a very complicated transformation. Such assumptions were indeed not lacking previously, namely as long as one believed that man could be descended from "four-legged" animals". According to KLAATSCH, the ancestors of man had "four hands", as was demonstrated for the oldest terrestrial vertebrates. They were "climbing animals" whose four gripping organs would have developed from fins. Limbs "that are designed as feet, i.e. that cannot perform services other than supporting and walking", are a regressive truncated development (KLAATSCH). Therefore, a hand can never result from a foot through evolution.

If we accept the opinion that man descends from quadrumanous creatures and not from quadrupeds, then all studies of the human hip joint that support an upright erection of man from the quadruped gait act on false assumptions or the results of such studies have to be interpreted differently than beforehand.

The statements about anatomical problems with the hip joint, which VON LANZ reported in 1949 at the orthopaedics convention in Munich and according to which the acetabulum roof is to be a phylogenetically new acquisition, are based on exact scientific investigations that are not to be doubted. Some of this deals with completely new findings, in particular when it comes to the vascularisation of the acetabulum that developed during the intrauterine embryonic phase. From the fact that the acetabulum is supplied from three different artery areas, VON LANZ draws the conclusion: "The sheer

number of these supply vessels indicate that they do not serve a building zone that is age-anchored in the phylogenetic basic plan. Such zones are supplied uniformly by a central main base. Also with regard to technical supply, the hip joint represents a new building site on which building material is to be procured from everywhere in the environment and in a variety of ways".

Anthropological prehistoric research has evidence that bipedalism is not a new acquisition, but rather is millions of years old.

Paleoanthropological and modern anatomical findings therefore seem to contradict each other. It therefore raises the question as to whether perhaps the findings that VON LANZ and his employees gained may have a different interpretation than before.

The human infant as a "secondary nest leaver" and "physiological premature birth"

VON LANZ himself builds a bridge to a different evaluation of his results to be reconciled with the findings from the primitive times of man in which he emphasizes with respect to the acetabulum roof that "the cartilage surrounding (the vessels) still has a embryonic character, is acapsular, and has many spindled cells in a uniform matrix".

When VON LANZ also only mentions findings on human embryos in the various stages of development up to the 7th embryonic month in his communication, then his allusion to a congress on LH is to be understood that the immaturity of the acetabulum - even at the time of birth - should particularly be stressed.

The immaturity of the hip joint is not a new concept in orthopaedic literature and in relation to LH. ROHLEDERER in particular stressed this and ultimately can the generally accepted expression of "congenital dysplasia" created by HILGENREINER also be understood as "immaturity"?

According to PORTMANN, in zoology two major groups of young development stages of animals can be distinguished between, even with mammals: Nest residents and nest leavers.

Nest residents belong to a lower organisational level and are characterised by short gestation periods and a high number of young per litter. As newborns, they do not have any hair or plumage, their sensory organs (eyes, ears) are closed by adhesions and the regulation of the body temperature must be done from the outside (mother). Examples are: Songbirds, rodents and marten-like predators.

Nest leavers are highly organised mammals with a specialized build and a richer brain development. They have a long gestation period and only a small number of offspring in each litter. The birth state of the nest leaver is in distinctive cases a nearly completed small form of the adult model with all of their instinctive reactions and neuromuscular functions. This group in particular includes hoofed animals, whose young integrate into the community of the herd and keep up almost immediately after birth in the wild.

Due to its pronounced helplessness, the newborn human appears to be assigned to the group of nest residents. The long gestation period and the predominantly singular offspring per pregnancy as well as the high cerebralisation, however, make the human also recognised as a nest leaver, such as the eyes and ears open at birth, which are closed intrauterine from the 3rd - 5th foetal month. The human already performs the "changes of the sensory organs characteristic of the nest resident in the womb" (PORTMANN) and is born in the state of a nest leaver with respect to the aspect of its sensory organs.

In other respects, however, man differs from the true nest leaver. While with this nervous system, the brain in particular is nearly fully developed at the time of birth, the human infant is born as a "pallidum being" (FOERSTER). All parts of the brain developed above the pallidum are still immature in his opinion and therefore are not suitable for functioning. The peripheral nerve tracts of the newborn have not yet matured everywhere. Their medullary sheaths form gradually after birth so that a state is first achieved in the 2nd - 3rd year of life that is close to that of an adult (A. WESTPHAL), cit. according to A. PEIPER). The development of the medullary sheaths is, as PEIPER stresses, not an absolute requirement for a functioning of the nerve tracts, since safe reflex movements have already been observed before the medullary sheath formation. However, conclusions can be made about the ontogenetic structural principle.

The fact that important features of the nest resident state have been overcome by human evolution or are overcome intrauterine, but on the other hand the species-related behaviour of the adult model is still missing in the newborn prompted PORTMANN to accept a birth state that is unique to man at the start his anthropogenic studies. He refers to this childhood form as a secondary nest resident, an expression that PEIPER refers to as insufficient, because the infant does not have a relationship to the nest. In a recent communication ("Goma", bulletin no. 3, 1960), PORTMANN assigns the secondary nest resident level not only to humans, but also to all primates, because "the nest leavers like the secondary nest residents together represent the higher level of the mammalian ontogenesis". KLINKE also believes that the designation of the human infant as a secondary nest resident is in no way sufficient. However, he emphasizes the view of PORTMANN that man is born into the world after the 9th month as a "physiological prematurity" and after that "undergoes another extrauterine foetal time of 12 months".

Already in 1903, E. VON LANGE discussed "The principles of the linear growth of man" in a detailed work: "The body growth of the newborn is still under the direct influence of energy that was formed in the late foetal period". Within the 1st year of life, the body length grows by 50% of the birth size and already in the 20th month of life achieves half that of the adult state. In 1922, SCAMMON again highlighted the foetal nature of early childhood growth (cit. according to DEBRUNNER and PORTMANN).

The birth state of the brain (and peripheral nervous system) also makes an important contribution to denoting the human infant as a physiological prematurity if man is to be considered as a secondary nest resident according to his high development stage in the mammalian species. "The smaller the brain is in relation to the brain stem or old brain, the shorter the pregnancy lasts. The further advanced the cerebralisation is, the more time the development in the womb requires. From comparative observations, it can be deduced that a hypothetical being with a cerebralisation similar to that of a human - but that would

have remained a monkey - would require a gestation period of 21 months. This is a whole year longer than the human development requires in the womb". (KLINKE)

The Maturation of the Extremities

The thoughts of PORTMANN regarding primary and secondary nest residents, nest leavers and the birth state of humans as a physiological prematurity have been dealt with twice before in orthopaedic literature: by DEBRUNNER in his monograph of the club foot and by HOFER in correlation to LH.

Using the findings of PORTMANN, HOFER hypothesises that the hip joints of newborns - pars pro toto - correspond to the state of foetuses prematurely released from the womb and therefore "are in a dependent state that requires longer care".

If this claim is true, then the hip joints of the newborn cannot yet be considered as functionally mature structures. The results of the anatomical investigations in this regard cannot be related to the tasks of the hip joints later in life.

PEIPER repeatedly emphasized that infants and small children are not small adults and are incorrectly assessed "if their performance is measured by the end goal towards which their development is heading.

According to the external impression that the newborn human makes in his (measured by the freedom of action of the adult) helplessness, one is immediately inclined to recognise the inability of the small one to carry loads [illegible word, guessing at meaning]. We know, however, that various organs such as the heart and kidneys are largely mature at the time of birth and fully functional. For this reason, it cannot be stated for the assumption that man is physiologically born too early that every functional unit of the newborn body is to be designated as immature. A hypothetical claim, as HOFER makes, requires scientific human evidence before it can be used as the working basis for [illegible] and therapeutic measures.

For the lower extremities, including the hip joints, it can be shown in various ways that they do not have any notable functional significance directly after birth, that they acquire these within the first year of life and ultimately by the 4th year of life are largely matured as standing and locomotion organs.

Most impressively, the development of the central and peripheral nervous system shows the regularity and order of the occurrence of the species-related neuromuscular relationships and therefore the inclusion of the functions provided for in the development plan.

The brain activity of the newborn is restricted to the brain stem, which is why it is referred to as the "pallidum being" by FOERSTER. In the course of the 1st year of life, the brain centres successively and in the same order as they have phylogenetically developed assume their activities up to the cerebral cortex.

The pallidum controls the mass movements of the young infant, which cannot yet perform targeted individual movements. Only after the maturation of the striatum can these occur, which inhibits the activity of the pallidum, and through the movement centres in the cerebral cortex starting to work (PEIPER - THOMAS).

This afferent development direction in the brain occurs in parallel to a cephalocaudale development direction from the brain to the spinal cord. "The brain stem is therefore the focus from which the development progresses in both directions, upwards to the new brain and downwards to the spinal cord" (PEIPER).

The principle of the descending development direction of the peripheral nerve tract was first observed on animal and later on human [illegible word]. However, it is also proven on a child within the 1st year of life as the extensive studies of PEIPER inter alia show the materialisation of certain reflexes and of chain reflexes as well as so-called supporting reactions when learning how to crawl, creep, slide and walk upright. Gradually through the development of the big brain, these reflexes are made superfluous and are inhibited (PEIPER ISBERT).

The stepping and climbing movements of the newborn, which PEIPER described in 1928 and 1953, are no more an expression of independent forms of movement as the creeping, swimming and climbing movements of young infants found by other others. These automatisms disappear long before the very beginnings of true independent movement and also cannot be carried over into these through regular practice. The walking and climbing movements of the newborn can therefore not be viewed as phylogenetic recollections of a walking ability present in the primitive times of man immediately after birth as it is with highly developed nest leavers. The conclusion therefore can also not be drawn that the hip joint was already developed at birth for a standing and walking function.

Due to the progressive maturation of neuromuscular relationships moving downwards from the brain stem to the periphery, there are first targeted coordinated performances at the arms and hands and first at the legs and feet at a later point in time. PREYER was the first to make this observation about an infant in the 19th century: "But it must be noted that the bilateral-symmetrical movement of the face muscles and the arms appears much earlier and more decidedly for reflexes than those of the legs" (cit. acc. to PEIPER). This was later confirmed by numerous other authors.

The cephalocaudale development direction again appears when learning how to crawl and creep, which are the first independent forms of locomotion of the young human. When crawling, the forwards movement only occurs through the arms: "apart from [illegible word] movements, the legs remain stretched and do not support the locomotion" (PEIPER). All four extremities are used to creep, but the movements of the legs are much slower and are interrupted by longer pauses than those of the arms.

The age at which crawling (locomotion only through arm usage without using the legs) and creeping (locomotion using all four extremities) are learned is illustrated by the later functioning of the legs over the arms. According to MAC GRAW, children between the 125th and 405th day of life were capable of crawling, i.e. on average on the 245th day of

life, and capable of creeping between the 275th and 665th day of life, i.e. on average the 340th day of life (cit. acc. to PEIPER).



Abb. 1 3,5 Monate alter Orang-Utan.
Die Arme sind aktiv, die Beine
werden untätig in Beuge-Abduktionsstel-
lung gehalten.

The great apes have a development that is completely identical. With them too, the arms are functional much sooner than the legs. G. BRANDES shows the orang-utan reared in the Dresden zoo at the age of 3.5 months (fig. 1) and writes the following about this: "We see here that in this hanging position and at an age of three months the front limbs are all active while the hind limbs are to a certain degree idly stuck to the body, which looks very similar to the intrauterine position". SCHENKEL reports on the Basel gorilla child "Goma" who at the start of the 3rd month of life began to grab for the edge of the basket with its hands and pull it towards himself. At the end of the 3rd month, it pulled itself into a type of crouching position and later tried to heave itself up with its legs, but could not reproduce this with certainty until the 4th month of life.

The principle of the cephalocaudal development direction can, however, not only be seen from more than just the way the extremities begin their species-appropriate functioning.

In considering LH, and here in particular with the evaluation of the anatomical examination results that VON LANZ communicated about the hip joint, it is necessary to pay particular attention to the skeletal maturation. The principle of cephalocaudal development direction can also be demonstrated here.

In the work "Biological data for paediatricians", LENZ published two tables (fig. 2 and 3) in which the bone core development upper and lower extremities up to the 5th year of life is listed according to the examinations of ELGENMARK. The figures indicate the average age in months at which in 25%, 50% and 75% of all examined children the bone cores were detectable.

Tabelle 1 Knochenkernentwicklung an der oberen Extremität bis zum 5. Lebensjahr. Die Zahlen geben das Alter in Monaten an, in dem bei 25%, 50% und 75% aller Kinder die Knochenkerne vorhanden sind (s. Elgenmark).

Knochenkern	Knaben			Mädchen		
	25 %	50 %	75 %	25 %	50 %	75 %
Hand und Handgelenk						
Capitatum	3,6	4,2	4,9	1,8	3,2	4,7
Hamatum	4,0	5,0	7,0	2,7	4,0	5,3
Distale Radius-Epiphyse	7,7	10,4	14,1	7,7	8,0	12,1
Triquetrum	21,1	32,0	45,6	22,2	27,8	34,4
Lunatum	36,7	49,8	57,8	29,8	34,1	50,4
Metacarpale I	25,5	31,4	34,0	16,1	19,8	22,7
" II	17,4	21,9	25,1	11,7	13,1	18,8
" III	17,6	23,3	26,5	13,0	15,9	18,3
" IV	22,6	24,9	29,4	14,6	17,2	19,9
" V	25,6	26,1	29,6	14,9	17,0	21,0
Proximale Phalange I	36,6	31,4	33,3	17,5	22,3	25,4
" II	12,2	15,1	21,7	10,2	11,1	14,4
" III	12,4	11,0	17,0	10,1	11,0	13,6
" IV	12,4	18,8	23,1	10,2	11,3	14,7
" V	17,5	25,5	25,7	12,8	11,5	18,0
Mittlere Phalange II	17,8	21,2	26,3	12,4	15,0	19,3
" III	17,0	23,1	25,7	11,8	14,9	18,8
" IV	17,0	22,9	25,6	12,1	14,9	19,3
" V	31,4	34,4	44,8	18,9	22,9	25,9
Distale Phalange I	13,0	16,3	23,6	8,8	11,0	17,5
" II	31,9	34,4	43,1	19,8	22,9	27,7
" III	22,6	28,2	31,1	12,5	23,3	25,0
" IV	22,8	29,3	32,7	14,0	23,5	24,3
" V	32,1	34,8	41,6	19,9	22,9	26,3
Ellbogen						
Capitulum humeri	3,7	6,0	8,7	4,3	5,7	8,0
Proximale Radius-Epiphyse	47,5	53,3	81 ¹	34,6	44,2	47,9
Schulter						
Caput humeri	0,7	2,1	3,6	0,7	2,1	3,8
Tuberculum majus	9,9	19,3	23,6	7,7	9,1	10,7
Processus coracoideus	3,7	4,0	10,1	3,6	6,4	7,3

¹ ergänzt nach Völsch und Harding (Lenz).

Abb. 2 ELGENMARK-Tabelle über das Auftreten röntgenologisch sichtbarer Knochenkerne in der oberen Extremität

Tabelle 2 Knochenkernentwicklung an der unteren Extremität bis zum 5. Lebensjahr (n. Elgenmark). Einteilung wie Tabelle 1.

Knochenkern	Knaben			Mädchen		
	25 %	50 %	75 %	25 %	50 %	75 %
Fuß						
Cuboid	0,8	2,0	3,7	0,6	1,7	2,5
Cuneiforme III	4,1	5,0	7,4	2,7	4,2	5,3
" II	19,0	25,5	38,3	11,4	20,6	24,3
" I	23,6	31,4	36,3	20,1	22,5	25,4
Naviculare	31,6	38,1	51,5	22,6	25,9	35,1
Distale Tibia-Epiphyse	3,9	5,7	6,7	4,7	5,6	6,6
Distale Fibula-Epiphyse	9,7	10,8	22,5	7,3	8,8	10,7
Metatarsale I	28,3	31,9	33,8	17,8	20,0	22,2
" II	34,8	39,0	45,2	23,1	25,9	28,6
" III	37,5	39,5	49,0	25,5	29,1	32,0
" IV	42,9	47,5	51,5	28,4	32,0	35,9
" V	43,7	48,2	55,7	32,1	35,0	43,0
Proximale Phalange I	24,3	28,8	32,7	17,2	19,6	20,0
" II	17,2	21,9	25,8	11,0	14,9	18,8
" III	14,7	20,8	23,4	10,9	12,3	16,8
" IV	16,0	21,8	22,4	11,0	13,3	19,3
" V	23,5	28,8	32,7	18,0	21,0	23,0
Mittlere Phalange II	21,7	24,3	28,6	11,0	16,9	20,0
" III	15,2	24,3	29,0	11,2	17,5	23,4
" IV	17,7	26,2	35,0	12,4	22,4	26,3
" V	29,0	35,1	47,4	20,0	25,9	35,7
Distale Phalange I	12,9	14,0	19,6	9,1	10,2	13,2
" II	34,2	39,5	47,3	22,4	29,1	33,0
" III	35,2	41,5	47,1	20,0	29,3	34,4
" IV	37,1	41,7	46,8	22,6	29,5	35,4
" V	36,7	39,5	49,5	23,1	30,1	36,0
Knie						
Distale Femur-Epiphyse	0,3	0,5	0,8	0,3	0,6	0,9
Proximale Tibia-Epiphyse	0,4	0,7	1,8	0,4	0,8	2,3
Proximale Fibula-Epiphyse	40,8	51,3	56,4	30,1	34,5	43,5
Patella	45,8	49,0	55,9	27,3	31,6	33,3
Hüfte						
Proximale Femur-Epiphyse	3,9	5,6	6,7	3,6	4,9	6,2
Trochanter major	43,2	46,1	51,5	27,2	30,2	34,0

Abb. 3 ELGENMARK-Tabelle über das Auftreten röntgenologisch sichtbarer Knochenkerne in der unteren Extremität

The many figures of these two tables are confusing and do not allow for a clear orientation. This is why the figures were added in the individual columns and average values were calculated by dividing the sums with the number of bone cores (upper extremity: 29, lower extremity: 32). These are recorded in the next table (fig. 4) and clearly show that in both genders the bone core formation on the skeleton of the legs appears much later than on the arms.

	O b e r e Extremität (29 Knochenkerne)	U n t e r e Extremität (32 Knochenkerne)
Knaben		
25 %	18,3 Monate	23,4 Monate
50 %	23,0 Monate	27,7 Monate
75 %	27,3 Monate	33,2 Monate
Mädchen		
25 %	13,0 Monate	15,8 Monate
50 %	15,9 Monate	19,6 Monate
75 %	19,7 Monate	23,3 Monate

Abb. 4

Abb. 4 Durchschnittsalter der Knochenkernentwicklung an oberer und unterer Extremität

The process was now continued in the same manner for the hand and foot skeleton alone, but for uniform functional reasons the distal epiphyses of the radius, tibia and fibula were also recorded. The sums acquired were divided in the same fashion as mentioned above by 24 (hand) and 26 (foot). The results are recorded in the following table (fig. 5). They again show the regularity of the subsequent skeletal maturation on the lower extremities compared to the upper. On the other hand, they also show that the cephalocaudal development direction not only applies to the extremities in general, but also that it determines the sequence of the skeletal maturation within the individual extremities.

	H a n d einschl. vordere Radiusepiphyse (24 Knochenkerne)	F u ß einschl. untere Tibia- und Fibulaepiphysen (26 Knochenkerne)
<u>Knaben</u>		
25 %	19,4 Monate	23,7 Monate
50 %	24,2 Monate	28,2 Monate
75 %	27,7 Monate	34,2 Monate
<u>Mädchen</u>		
25 %	13,5 Monate	16,0 Monate
50 %	16,4 Monate	20,1 Monate
75 %	20,6 Monate	24,1 Monate

Abb. 5

Abb. 5 Durchschnittsalter der Knochenkern-
entwicklung an Hand und Fuß

The figures from the tables above appear to be values without a regular relationship. However, if you correlate the average times of bone core formation on the upper extremity to that of the leg and foot (fig. 6), then this results in a delay factor of 0.82 for the entire skeleton of the lower extremity as well as for the foot skeleton compared to the upper extremities, i.e. the lower extremities are approximately [illegible text] % behind the upper extremities in the skeletal maturation.

	Vergleich der Werte aus den Tabellen Abb. 4 und 5	
	Arm : Bein	Hand : Fuß
<u>Knaben</u>		
25 %	18,3 : 23,4 = 0,78	19,4 : 23,7 = 0,82
50 %	23,0 : 27,4 = 0,84	24,2 : 28,2 = 0,86
75 %	27,3 : 33,2 = 0,82	27,7 : 34,2 = 0,81
<u>Mädchen</u>		
25 %	13,0 : 15,8 = 0,82	13,5 : 16,0 = 0,84
50 %	15,9 : 19,6 = 0,81	16,4 : 20,1 = 0,82
75 %	19,7 : 23,3 = 0,80	20,6 : 24,1 = 0,85

Abb. 6 Relation der in Abb.4 und 5
niedergelegten Werte

The preference of the arms and hands in the skeletal maturation and in the formation of independent forms of movement, which can be found in all primates, justifies the assumption that the upper extremities have a greater significance in the 1st year of life than the lower extremities. The more timely completion of the neuromuscular functions on the arms requires an earlier maturation of the skeleton, namely the supporting structure with contact points for the power and movement organs.

The legs and feet, on the other hand, are first needed later (near the end of the extrauterine foetal time) in the natural blueprint as standing and walking organs. Their skeleton and nerve-muscle connections remain immature longer than on the arms.

After E. VON LANGE discovered the foetal character of longitudinal growth during the first two years of life, MATTHIAS now indicates that "the small child phase is still dominated by the rest of the embryonic proportions x) in its entire course of growth (large head, large round torso with forward belly, relatively small leg length x)". The small child phase is to be understood as the time from the 1st to the 5th year of life. The relative leg length grows constantly during the entire growth time. According to LENZ, it is 37.0% for boys and 37.1% for girls after birth and increases until the completion of growth at 50.5% or 50.0% per cent. The relative arm length, on the other hand, fluctuates from birth to completed growth between 42% and 45% in boys and for girls only back and forth between 42% and 43.7%.

The different behaviours of proportions of legs and arms during growth make it evident that the upper extremities resemble their final shape at the time of birth far more than the lower extremities.

Finally it should be pointed out that the time difference in the skeletal maturation of the upper and lower extremities does not last for the entire period of growth. The skeletal maturation is completed with the ossification of the growth plates. According to PATERSON (cit. acc. to W. LENZ), the closure of the epiphyseal plates occurs sooner on the long hollow bones than on the upper bones. Thus, for example, the upper femur epiphyseal plates ossify in girls by 17 and in boys by 18 years while the upper epiphyseal plates of the humerus close in female individuals by age 18 and in men first at 21 years old.

The later skeletal maturation of the lower extremities is therefore a specific peculiarity of early childhood.

An innate nature of human development after birth can be seen in this mode of maturation. In infants and small children (to speak with PEIPER), the legs do not yet have the significance of the arms and hands in the intimate mother-child relationship. These are needed much more as receptors in the co-existence of mother and child than, *sit venia verbo*, than the mother's open legs.

The following can be noted from the aforementioned: "Humans are to be assigned to the group of "nest leavers" in accordance with their high organisational level in infancy. However, humans do not complete the full development in the womb, which is

attributable to a true nest leaver, but rather are born as "physiological prematurities". This foetal condition at birth moves humans to "secondary nest leavers".

The embryonic character of the birth state is not evident on all body organs. However, it can be found primarily in the nervous system above and below the brain stem and therefore inevitably also in the neuromuscular functions of the extremities. The longitudinal growth and the proportions of the body, in particular those of the legs, still have foetal characteristics upon birth.

The skeletal maturation of the extremities undergoes a different mode in early childhood than in later development periods. In the first five years of life, skeletal maturation occurs in the lower extremities about 20% later than in the upper extremities, but is completed on lower extremities sooner than the upper.

As a result of the cephalocaudally directed maturation of the efferent nervous tracts and the (likely associated) time difference in the skeletal maturation of arms and legs, the functional significance of the upper extremities is predominant in the 1st year of life while the functional significance of the first gradually increases in the 2nd year of life. The lower extremities of newborns and young infants and their functional units (e.g. joints) are therefore to be viewed as physiologically relatively immature. For this reason, the results of anatomical and joint-mechanical examinations on the lower extremities of foetuses, newborns and infants may not be evaluated by scales that were acquired on mature structures of older children or even adults of the same species.

The physiological reduced extension of the infant hip joint, its causes and its meaning in the pathogenesis of hip luxation

There can therefore be no doubt that the hip joints of every newborn are still physiologically immature, which HOFER – taken as represented - accepted without further evidence. They are moving organs, but are not preformed for quadruped or for biped walking. Their acetabulum roofs are not up to the task of bearing loads.

It is therefore not necessary to clarify the assumption represented by VON LENZ that humans walking upright and the structural form of their hip joints are a phylogenetically new acquisition and for this reason the acetabulum roofs are not yet completely secured around the seemingly unfinished formation of the hip joints. This arises much more from the, in some respects, physiologically immature birth state of humans.

The term "immature" in relation to newborns - since this is physiological - can of course only be a relative term. For every child born at a normal time and developed normally is a complete being at every stage of development that is always most excellently adapted to his natural surroundings". "...the child is adjusted to a certain environment by nature, namely always the same environment, and is adapted....to it. This is his mother". (PEIPER)

The physical forms and functions of the newborn and infant as well as their behaviour must be understood from this intimate bond of child to its mother and the child's precise adjustments to this relationship.

The infant's legs are not yet ready for standing and walking! Phylogenetically seen, only the grabbing reflexes and the supporting reactions are necessary: the former to hold onto the mother and the latter perhaps to reach the mother's breasts.

Since the mother represents the only environment of the child in the early infancy age under natural conditions, such as those to be encountered in every case still among anthropoids, the child's legs must be adapted to life on the body of the mother. A stretched position of the legs as man assumes when standing and walking would be meaningless here, because it saps energy and does not provide enough surface contact with the mother, especially for temperature-sensitive regions of the child's body (front of the torso, inside of the thigh).

The legs of the young anthropoid child mainly adopt a straddling and bending position.



Abb. 7 Der 1 Tag alte Gorilla "Goma" in der für alle Primaten im Säuglingsalter typischen Beinhaltung.

Except for the toning muscle work triggered by the foot grabbing reflex, almost only passive holding mechanisms (ligaments) are stressed here. At times, the straddling-bending position includes a slight outward rotation of the legs in the hip joints. Fig. 7 shows this leg position very clearly with the newborn, which is a one-day old gorilla baby "Goma" from the Basel Zoo.

The newborn human holds its legs in the same fashion, as shown by the studies of NAUMANN, PEIPER and THUROW. The resting-sleeping position described by these authors as a typical position of the legs (and arms) was found by NAUMANN to exist in all studied newborns, in 50% of 6-8 month year old infants and still in 50% at the end of the first year of life (fig. 8).

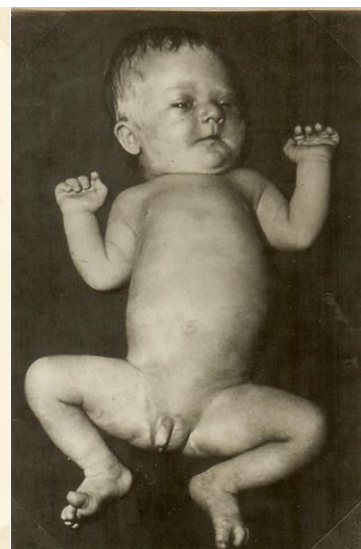
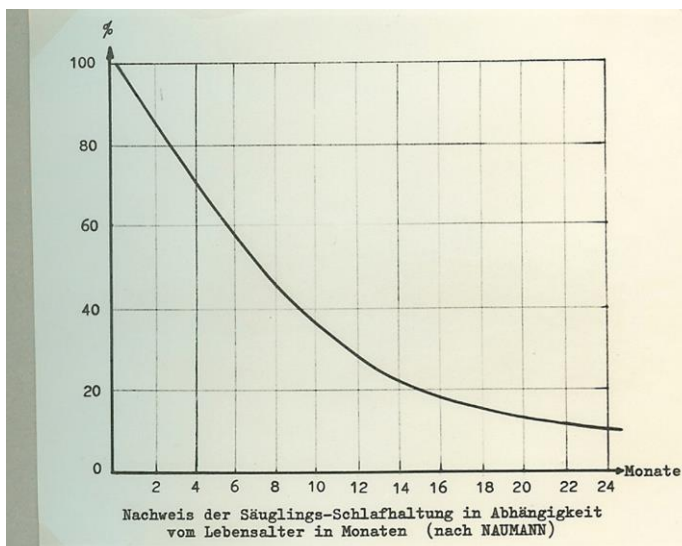


Abb. 8 Häufigkeit der Säuglings-schlafhaltung, abhängig vom Lebensalter (nach U.R.NAUMAN)

Abb. 9 3 Wochen alter Säugling in typischer Ruhe-Schlaf-Haltung

The resting-sleeping position of the newborn (fig. 9) is best understood from the intrauterine position of the foetuses at the end of the pregnancy. It is known that the legs of the foetuses are bent at the hip and knee joints at an acute angle and the hip joints are slightly abducted and outward-oriented. After birth when the surrounding pressure of the wall of the uterus has subsided, the intrauterine egg shape in which the foetal body was forced unfolds to a certain degree and falls apart from the gravity, opening like a fan.

This process of postpartum unfolding that occurs with nearly all forms of life, both animals and plants, alone does not explain the flexion abduction position of the legs in the hip joints. Among others, PEIPER assumes that the central nervous influences are responsible for the coming about of the resting-sleeping posture, which explains this phenomenon in part, but not completely for the posture of the legs.

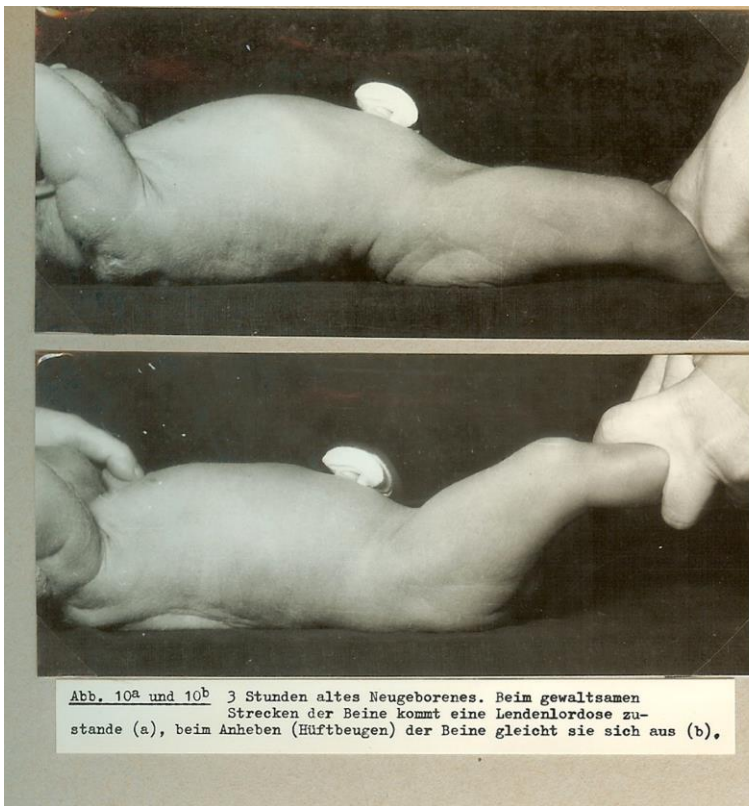


Abb. 10^a und 10^b 3 Stunden altes Neugeborenes. Beim gewaltsamen Strecken der Beine kommt eine Lendenlordose zustande (a), beim Anheben (Hüftbeugen) der Beine gleicht sie sich aus (b).

In my own investigations of newborns, it stood out that they cannot completely stretch their legs in the sagittal plane. If the thigh is passively pressed to the base, then the pelvis tilts forward and thus to the lordosis of the lumbar portion of the spine (fig. 10 a), which is an non-physiological spinal posture for newborns and infants. Only with the flexing position of the thigh does the age-appropriate stretched position of the lumbar portion of the spine come about (fig. 10 b). Such a reduced extension in the hip joints could be caused by muscular,

ligamentous or athrogenic reasons. To clarify this question, 24 freshly newborn pelvises were examined x). The pelvises, together with the lower lumbar area of the spine (L3 to L5), femora and knee joints, including the muscle sheath, were subcutaneously taken from unprepared corpses. The musculature was manually prepared while strictly protecting the capsule-ligament apparatus of the hip joints so that a pure skeletal-capsule-ligament specimen was available for the measurements.

In measuring the extension inhibition in the hip joints, the measurement proceeded according to SCHNELLE's recommendation that the loin lordosis was completely compensated for, which is particularly justified in studies of newborns and infant pelvises, because at this age the spinal column either has a complete stretched position or

even a total kyphosis. The sacrum and lower lumbar region of the spine were affixed flat on the level surface and the pelvis was set in the frontal plane using a spirit level, which was laid on the spinae iliacae ventrales. A Kirschner wire was shot through the condyles of the femora, which was used to precisely set the condyle axis in the frontal plane. The weight of the two femora connected with the Kirschner wire exerted an approximate physiological tension on the ligament-capsule apparatus of the hip joints, i.e. the hip joint capsules and their reinforcing ligaments were extended in a manner corresponding to the natural conditions of life under experimental conditions. A precision protractor was now used to measure the angles that the femoral longitudinal axes formed with the flat surface. The result of these measurements is recorded in the table overleaf.

According to SCHNELLE, if you assume that the hip joints of an adult can be extended to an angle of 180 degrees, then the results obtained show that an average reduced extension of the hip joints in newborns and infants of 42.9 degrees (right hip joint 42.2 degrees, left hip joint 43.6 degrees) is physiologically present. This is another indication that the hip joints of newborns and infants cannot be considered in the same light as those of walking small children and adults.

17 of the studied pelvises came from children who died at birth or within a few hours after birth. Two of the children lived for 3 and 5 days and one each lived 15, 21 and 104 days. There was no striking difference in the reduced extension of the hip joints between the children who survived for a longer period of time or who died during or soon after birth. However, the values measured for the 104 day old child (specimen 22) are very low and the reduced inhibition discovered on the right hip joint is the lowest in the entire table, but almost the same values were also found on other specimens that came from children who did not survive birth.

Theoretically, the conclusion is obvious that the physiological hip joint reduced extension of newborns and infants is resolved by learning to walk, as otherwise a stronger pelvic tilting forward and a pronounced loin lordosis would have to be found in standing and walking small children, which is not the case. Examinations on three pelvises from 9-month year old children (which were carried out in another context and therefore were not recorded in the table) showed no reduced extension in both hip joints for two pelvises - of which one was a from a child with Down's syndrome and the other of which was a normal pelvis.

x) I would like to thank chief physician Dr. SCHEID, director of the Pathology Institute at the Dresden-Friedrichstadt Hospital, for his friendliness in providing me these pelvises.

Overview of the specimens examined

No.	State of maturation	Body length and weight	Gender	Reduced extension right in degrees	Reduced extension left in degrees	Reduced abduction right in degrees	Reduced abduction left in degrees	Age
1	Mature	49 cm, 2450 g	M	30	30			Ø

2	Mature	48 cm, 2650 g	F	33	33			Ø
3	Mature (transferred?)	54 cm, 3400 g	M	35	40	25	30	Ø
4	Nearly mature	50 cm, 2660 g	M	28	30			3 days
5	Mature	48 cm, 3510 g	F	52	47			4 hours
7	Mature	51 cm, 3510 g	F	53	53	15	15	4 hours
8	Nearly mature	48 cm, 2850 g	M	45	45			Ø
10	Mature	49 cm, 2850 g	M	57	54			2 hours
12	Mature	49 cm, 2500 g	F	41	42			5 days
13	Mature	50 cm, 2500 g	M	36	43			3 days
14	Early birth, end of 8 th month	39 cm, 1150 g	F	50	55			Ø
15	Mature	47 cm, 1150 g	M	39	38			Ø
16	Mature	51 cm, 2200 g	M	31	32	20	22	15 days
17	Mature	52 cm, 3610 g	M	45	46	37	41	21 days
18	Mature	51 cm, 3850 g	F	52	56	26	28	0.5 hours
19	Transferred	59 cm, 4400 g	F	47	49	39	32	Ø

20	Early birth, 8.5 months	43 cm, 2150 g	M	72	74	10	18	Ø
21	Mature	50 cm, 2800 g	M	51	51	25	23	Ø
22	Mature	53 cm, 3110 g	M	26	30	36	34	104 days
23	Early birth, end of 8 th month	40 cm, 1340 g	F	34	36	24	30	Ø
24	Early birth, end of 8 th month	40 cm, 1520	M	43	40	31	37	1 hour
25	Mature	50 cm, 1800 g	F	40	40	42	35	5 hours
27	Mature	52 cm, 2800 g	F	42	52	23	23	Ø
28	Transferred	55 cm, 3850 g	M	30	30	45	38	Ø

On the third pelvis, the right hip joint was healthy and had a reduced extension of 32 degrees. The left hip joint was sub-luxated and showed a reduced extension in the middle position of the femur of 15 degrees, but showed full extension capability up to 180 degrees with the outwards rotating position, which will be discussed more later. With this pelvis, it must also be taken into consideration that the child had received a double-sided cast in the LORENZ position 17 days before his death, which was worn for 2 weeks. The small number of examined pelvises of older children does not permit any conclusion to be made about at what age the physiological reduced extension of the hip joints of newborns is resolved. All the same, it is striking that in the examination of three pelvises from 9-month old children, two of the same exhibited no reduced extension in the hip joints.

An observation of the movement mechanism of the hip joints of the newborn pelvis makes it possible to assume a relationship between the physiological reduced inhibition and the resting-sleeping position of the infant: When the pelvis was fixed to the subsurface in the manner described above, then the femora could not be held in the sagittal plane without special means. Rather, because as a result of the reduced inhibition they could not lower into the sagittal level on the surface, they oscillated sideways into a flexion abduction position that corresponds to the resting-sleeping position.

The resting-sleeping position of the legs of the infant is therefore not only due to a reflexive muscle tone, but also due to the age-appropriate reduced inhibition of the hip joints. The examinations of U-R. NAUMANN have shown that 70% of all children give up the infant sleeping position within the 1st year of life and then assume a position when

sleeping in which one or both legs are stretched out. This allows for the assumption that the physiological reduced extension of the hip joints is overcome in the 1st year of life, because a relaxed extension of the legs when sleeping would not be possible if the reduced extension continued.

The question was already raised asking what causes the physiological reduced extension in the hip joints of newborns. A hypertension of the muscles alone cannot be responsible for this, since the reduced extension was also regularly found on the muscle-free skeleton-ligament specimen of the newborn pelvis.

According to remarks from ROHLEDERER regarding the pathogenesis of hip luxation, under certain conditions the early embryonic egg shape of the hip joint body remains until birth, whereby postnatal stretching of the legs results in a traction of the joint and therefore to luxation. It is therefore necessary to remember that the reduced extension of the hip joints is caused under certain circumstances by an incongruence of femoral heads and acetabulums.

Therefore on 15 specimens the diameter of the femoral heads, i.e. a total of 30 femoral heads, were determined with a precision sliding calliper in the direction of the femoral longitudinal axis and perpendicular to this. The measurement results are recorded in fig. 11. They show that a spherical femoral head can only very rarely be found with longitudinal and transverse diameters of the same size. On the specimens, the transverse diameter on the right femoral head was on average 0.37 mm smaller than the longitudinal diameter and on the left femoral head the transverse diameter was 0.46 mm smaller than the longitudinal diameter. The by far largest difference between the two diameter heads of over 10% or over 11% was remarkably found in specimen 4, which came from a child who had 6 toes on each foot and 6 fingers on each hand and who had cardiac malformations. Size differences between the right and left femoral head of +1.0 mm up to -0.5 mm were also found.

Messergebnisse an Oberschenkelköpfen

Präparat- Nummer	Kopfdurchmesser in Millimeter			
	rechts		links	
	längs	quer	längs	quer
2	16,4	15,6	16,2	15,1
4	18,4	16,7	18,4	16,5
15	14,1	14,7	14,7	14,5
16	14,1	14,3	14,0	13,8
17	19,0	18,6	19,4	18,5
18	16,1	15,8	15,8	15,6
19	18,1	17,3	18,1	17,7
20	12,7	12,9	12,7	12,9
21	15,1	14,9	15,5	14,8
22	18,1	17,1	18,1	18,1
23	11,8	11,8	11,6	11,9
24	12,5	11,9	13,0	12,2
25	14,0	14,1	14,0	14,1
27	15,8	15,7	15,8	15,5
28	20,0	19,3	19,7	19,1
29 292 Tage alt	20,4	20,2	19,8	19,8

Abb. 11 Messergebnisse an
Oberschenkelköpfen

The non-spherical shape of the femoral head of course also causes an unrounding of the acetabulum, since there is no "empty" space within the hip joint. Thus far my own examinations coincide with those of ROHLEDERER. However, a traction of the hip joints by rotating the different sized longitudinal and transverse diameters of the hip joint bodies when stretching the legs could, however, not be found in any of the examined pelvis specimens. The cartilaginous wall of the acetabulum was in any case so soft and malleable that it adapted ideally to the femoral head in any position of the femur and adhered to the capsuleless specimen (although it is known with newborns that the acetabulum does not even cover half of the femoral head) such that it could only be removed from the socket by pulling towards the femoral neck axis with some force. The deformability of the cartilaginous socket wall is so extensive on the fresh pelvis specimen of the newborn that is not set in formalin that there would have to be a very significant size difference of the head diameter to cause a traction of the joint body when stretching the legs, which however has not yet been described.

The excellent adaptability of the cartilaginous socket to the usually unround femoral head also negates the problematic question posted above as to whether the physiological reduced extension of the hip joints in newborns is based on an incongruence of the joint bodies. The reduced extension therefore has to have another cause.

The third option that the reduced extension is caused by ligaments was therefore investigated.

It is known that the hip joint is equipped with 5 ligaments, 4 of which are extracapsular or are woven into the fibrosa of the joint capsule and reinforce it. The fifth ligament, Lig. teres femoris, is intracapsular.

Of the extracapsular ligaments, the annular ligament, Zona orbicularis, is not considered as a function reducing extension due to its position and orientation. Of the three other ligaments, Lig. pubocapsulare, Lig. ischiocapsulare and Lig. iliofemorale (BERTINI), which pull all of the uni-direction coiled windings towards the femur, the latter in particular is known to prevent a hyperextension of the leg in the hip joint, thus acting as a passive holding apparatus when standing upright. To meet this task, the origin and onset of the Lig. iliofemorale are osseously anchored while the other extracapsular ligaments emanate on the bone, but mostly insert within the hip joint capsule. Furthermore, the Lig. BERTINI is designed to be much stronger than the Lig. ischiocapsulare or even the Lig. pubocapsulare. It is one of the strongest ligaments in the body" (BRAUS - ELZE).

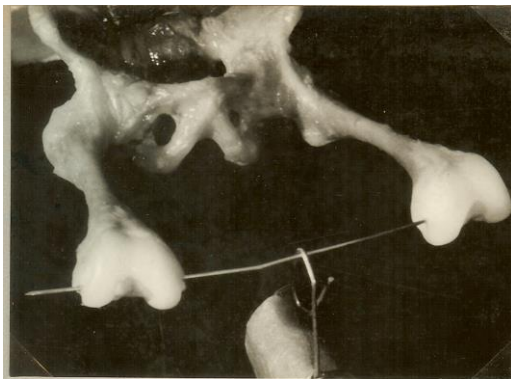


Abb. 12 Besonders am linken Hüftgelenk ist das Vorspringen der Pars medialis des Lig. iliofemorale bei Streckung der Femora durch Gewichtszug deutlich zu sehen.

seen in fig. 12.

The capsular nature of the reduced extension in the hip joints of newborns emanates from load tests on intact skeletal capsule specimens. For this purpose, the femora were connected by a Kirschner wire in the condyle axis so that they could not oscillate sideways in the abduction position. The specimens were fixed to the lower lumbar area of the spine with a strong clamp so that the pelvis and femora floated freely in the horizontal plane. The weight of the femora could not overcome the reduced extension (fig. 13). If a load of 100 g was hung on the Kirschner wire (fig. 14), then the extension in the hip joints only succeeded a little further. Due to the lever principle and as a result of the femur length, the weight hung on the femoral condyles acts on the pelvis with at least ten times the strength, so

The tremendous thickness of the ventral and proximal portions of the hip joint capsules caused by the Ligg. iliofemorale also stood out on the examined newborn and infant pelvises. The Pars medialis of the BERTINI ligament occasionally jumped out of the capsule level as if coiled upon extension of the hip joint using a weight, which can be

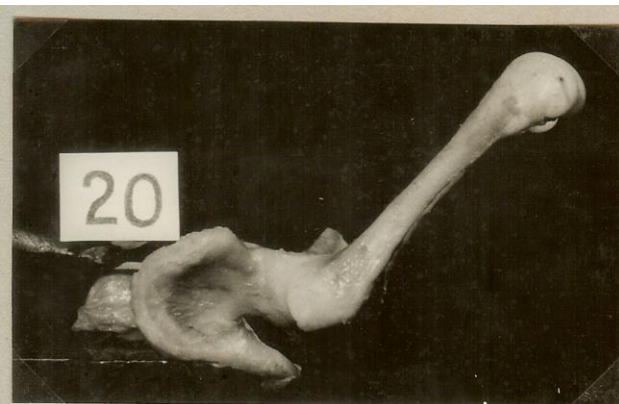

Abb. 13 Die kapsulär bedingte Streckhemmung der Hüftgelenke wird durch das Eigengewicht der Femora nicht überwunden.

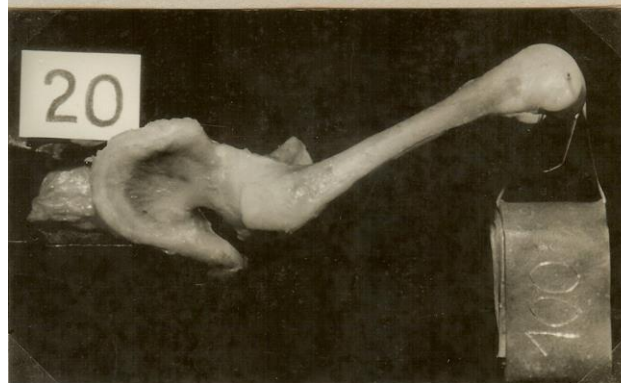


Abb. 14 Auch bei einer Belastung mit 100 g ist keine wesentlich weitere Streckung der Hüften möglich. Es kommt aber bereits zur Verwringung des Beckens in den Knorpelverbindungen.

with at least 1 kg under the test conditions. This therefore resulted in a twisting of the pelvis in the half joints and synchondroses, such that it can be seen in fig. 14 that the symphysis is lower than in fig. 13.

It was natural to think that the medial thigh of the Lig. iliofemorale has a significant impact on the physiological reduced extension of the hip joints in newborns. In order to clarify this question, the ventral-proximal portion of the hip joint capsule together with the Lig. iliofemorale on several specimens and the hip joint capsule up to the BERTINI ligament on other specimens were removed and then the hip joints were stretched with increasing force.

With the aforementioned specimens, there was a ventral luxation of the femoral head from the socket already at a low application of force, as BOEBEL observed in his studies on newborn pelvises. Occasionally the weight of the femur alone was enough to cause the luxation. If the luxation was prevented in that the femoral head was pressed into the socket from above with a finger, then this resulted in an equally large reduced inhibition in the hip joint as with an intact joint capsule.

This means that the Ligg. ischiocapsularia, with medial-caudal to lateral-cranial running fibres, are in a physiologically shortened condition in newborns and therefore cause a reduced extension of the hip joints. Now the leg was stretched in the hip joint with increasing violence under the same test conditions, i.e. while retaining the femoral head in the socket with a missing Lig. iliofemorale. With different uses of force, but in every case, there were first ruptures and then finally tears of the still existing capsule portion, usually near the capsule approach at the femoral neck, before achieving full extension. Neither the Lig. ischiocapsulare nor the much weaker Lig. pubocapsulare, nor both ligaments together were therefore able to sustain the physiological reduced extension of the hip joints of newborns. They tear when force is used and, as a result of their capsular insertion, are stretchable under the effect of a permanent stretching force.

The second series of tests where the Lig. BERTINI was preserved, but the other joint capsule with its ligaments was completely removed, led to different results: the stretching tests (where, like in the first series of tests, the condyle axis was held in the frontal plane) did not cause any luxation of the femoral head. Rather, this was pressed against the rear-lower quadrant of the socket with considerable force so that the soft cartilage wall of the socket there was bulging slightly. Even with the greatest of force applied, in no case was the physiological reduced extension of the hip joints completely overcome or the Lig. iliofemorale torn. Rather, as a result of the application of force, there was a considerable distortion of the pelvic bone in the half joints and cartilage joints as well as a bending of the femoral shafts, which might have resulted in the same fracture if even greater force was applied.

The different behaviour of the femoral head in these two series of tests is due to the ventrolateral position of the socket and the age-appropriate antetorsion of the coxal femur end. Due to the oblique forward-sideways-downward oriented arrangement of the acetabulum in the pelvic ring, there is insufficient counterhold of the femoral head at the front pelvic wall when stretching the leg, especially since in the first year of life it is twisted by more than 30 degrees before the condyle axis (frontal plane). The femoral head braces itself against the dorsal surface of the Lig. iliofemorale, which not only

prevents a ventral luxation, but also protects the ventral edge of the acetabulum from overload due to its rigidity. Dorsally, the socket wall covers the femoral head far more with the further possible extension than ventrally, so that if the capsule-ligament apparatus is eliminated there, a luxation cannot occur as easily as in front. However, the rear-upper quadrant of the socket wall is not sufficiently ligamentously protected against overload, an observation that is essential for the occurrence of LH, which is why we shall return to this.

The second series of tests was modified into a third, in which the Pars lateralis was stripped away from the Lig. iliofemorale so that only the Pars medialis of the BERTINI ligament remained. Under these conditions, when the leg was stretched there was a luxation of the femoral head at the cranial point of culmination of the acetabulum. If the luxation was prevented via counter-pressure with a finger, the tests led to the same results as with the second series of tests. If, however, the Pars medialis of the Lig. iliofemorale was removed and its lateral side was preserved, then no luxation occurred, but the physiologically reduced extension of the hip joint diminished somewhat or it was usually corrected with a jerky snap after overcoming over a little resistance.

The cause of the snapping phenomenon could only be intra-articular, since changes to the lateral side of the BERTINI ligament did not occur and, as already described, the soft cartilaginous socket wall ideally adapts to the usually non-spherical femoral head in any position.

It was therefore tested in a fourth series of tests on a completely capsule-free hip joint whether the Lig. teres femoris has an extension-reducing function, especially since it is questionable according to "BRAUS -ELZE whether as an inhibitory ligament it is important for extreme movements in the human hip joint".

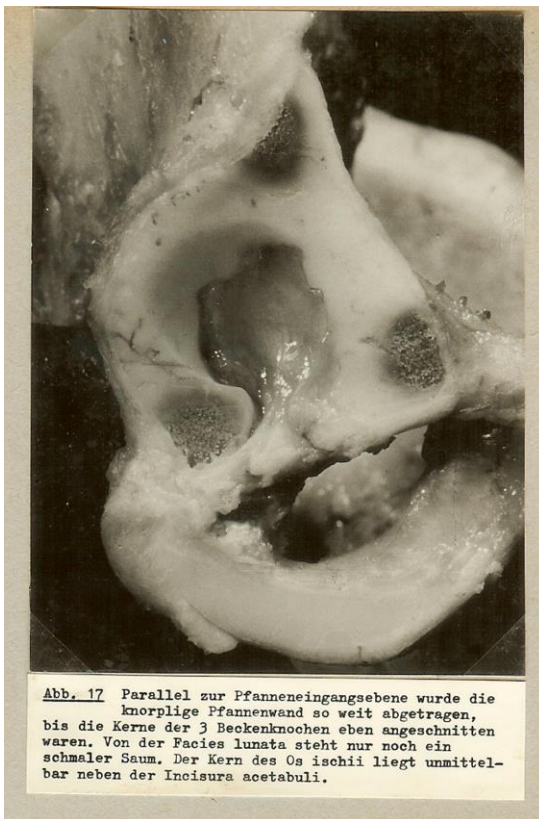The Lig. teres femoris originates in the ventral lower quadrant of the acetabulum at the Lig. transversum acetabuli and the front edge of the Incisura acetabuli. Its origin is therefore at an extremely strong ligament and is osseously affixed, which ensures a particularly firm anchoring. The insertion point of the Lig. teres femoris is (when viewing the femur in the stretched position) in the dorsal lower quadrant of the Caput femoris in the Fovea capitis femoris. This was, however, not formed on any of the total of 60 studied femoral heads as a pit, but rather always as an elongated furrow that runs in the direction of the head equator - splitting the rear lower head quadrants roughly radially in the middle. Embedded in this groove is the Leg. teres so that it only slightly protrudes out of the level of the femoral head. The point of adhesion of the ligament to the still cartilaginous femoral head in a newborn is considerably wider than the head furrow just mentioned.

The Incisura acetabuli represents a gap in the cartilage cover of the acetabulum in which the Lig. teres allows a certain freedom of movement without this being crushed between the femoral head and socket. A similar task is given to the head furrow, which runs from the Fovea capitis femoris to the equator. The axis of the Incisura acetabuli is oriented from the ventral-distal to the socket centre. An approximately same direction is taken by the head furrow, if the femora of newborns are kept in the physiological bending position.

However, if the femora on the capsule-free specimen is stretched in the upright position for ambulatory children and adults, then the axes of the Incisura acetabuli and head furrow are twisted against each other by 45 - 70 degrees, the Lig. teres is drawn out of the head furrow and its wide approach at the femoral head is rotated in order to finally, together with a piece of the head cartilage, tear away at its insertion point, usually with a noticeable jolt. However, if no additional stretching force, except for the weight of the femora, is allowed to act on the capsule-free hip joints, then the femora remain in approximately the same physiologically bent position as is to be found both on the closed capsule-ligament specimen as well as on the living newborn.

The intracapsular Lig. teres is therefore physiologically shorter both in the newborn and infant as are the extracapsular ligaments of the hip joint (with the exception of the annular ligament) than in the later years of life. Together with the Ligg. iliofemorale, ischiocapsulare and pubocapsulare, it causes the physiological reduced extension of the hip joints of newborns.

The extension-reducing effect and task of the Lig. teres can, however, only be viewed as low, since it is cartilaginously anchored at its insertion point and tears away from there easily upon an increasing, non-physiological stretching of the hip joint. Before the stretching leads to a tearing out of the Lig. teres, a twisting of the ligament occurs that leads to a mechanical restriction of the blood vessels running in the ligament.



While it was possible with all of these studies to easily tear out the Lig. teres from its onset on the femoral head by stretching the femur or pulling on the ligament in the longitudinal direction, in no case, even with using great force, was the Lig. teres successfully removed from its source. Its anchoring in the bone - the core of the os ischii already in a newborn already reaches close to the incisura acetabuli compared to those of the os pubis (fig. 17) - and to the Lig. transversum acetabuli proves to be extremely strong. Also due to the yielding of the socket window, there was never a twisting of the Lig. teres at its origin when stretching the femur as regularly occurred its insertion point.

These observations explain the findings that were often found in the surgical repositioning of congenital hip dislocations: avascular Lig. teres femoris (obliteration of the vessels due to twisting, longitudinal

tension and pinching) or complete absence of the Lig. teres (which tears off at the femoral head and disappears shrunk in the interleaf fat of the acetabulum).

The following conclusions can be derived from the study results:

- 1.) The reduced extension of the hip joints of newborns and infants is primarily ligamentous in its cause and is due to a shortness of the intracapsular and extracapsular hip joint ligaments typical of the birth state of primates (with the exception of the annular ligament). It is therefore justified to denote this reduced extension as physiological.
- 2.) Of all of the hip joint ligaments, the Lig. ilio-femorale (BERTINI) in particular causes the reduced extension, since it is by far the strongest, but also the only hip ligament whose origin and onset are anchored in the bone.
Due to their capsular insertion, all other hip ligaments can be stretched and damaged much more easily than the BERTINI ligament and can therefore cannot withstand the physiological reduced extension of the hip joints in the event of prolonged exposure to stretching forces.
- 3.) At the Lig. iliofemorale, the Pars medialis in particular has the task of preventing a full extension of the hip joint. The Pars lateralis of this ligament, which is three times thicker than the Pars medialis and is stronger than the Achilles tendon and patellar ligament (BRAUS - ELZE), must be viewed as a safety device in newborns and infants for avoiding a cranial dislocation of the femoral head when acted upon by stretching forces. As is known, the acetabulum does not even cover half of the femoral head at the time of birth and only in the course of extrauterine maturation does the hip joint form into a real nut joint where a cranial dislocation is prevented by the bony acetabular roof. In the first months of life, the cranial part of the soft cartilaginous acetabulum is not yet secured in its form by the ilium core, as will be the case when completed. It therefore requires a safeguard that lies outside of the joint body. This is taken over by the extraordinarily strong and unyielding Pars lateralis of the BERTINI ligament, against which the femoral head can brace itself when the hip joint is stretched. Due to this function of the Pars lateralis of the Lig. iliofemorale, the cranial culmination section of the acetabulum (the subsequent load-bearing zone of the acetabular roof) is protected from deformation and overload.

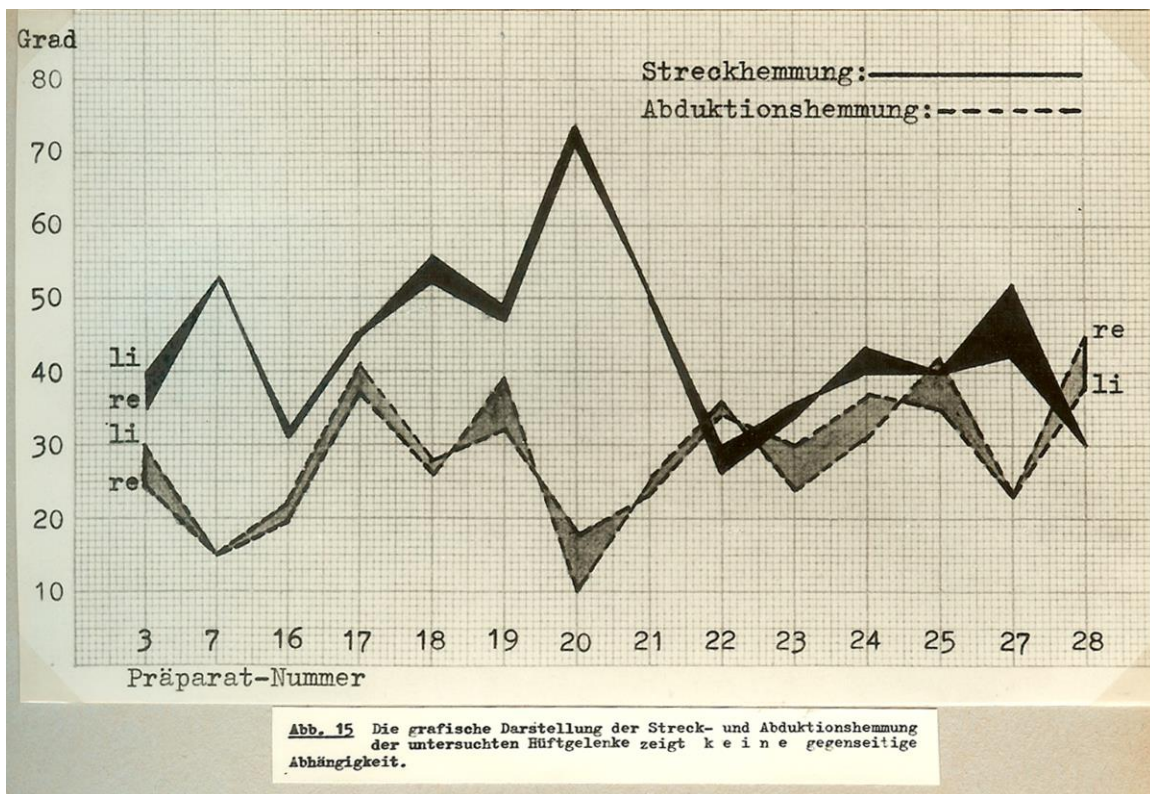
The abduction inhibition of the hip joint

The spine of the newborn child has a slight total kyphosis or full stretched position and the newborn's pelvis is tilted backwards with respect to the spine. In the first months of life, the child is not yet able to lie on a supine position with a permanently lordosing lumbar area of the spine in order to thus compensate for the physiologically reduced extension of the hip joints and to be able to position the stretched legs in a planar fashion. The stretched position of the lumbar region of the spine, the rearward tilting of the pelvis and the physiologically reduced extension of the hip joints would force the child to keep his or her legs bent in the sagittal plane. However, since this is impossible without active muscular work, the legs bent in the hip and knee joints fall over laterally and oscillating into the resting-sleeping position of the infant due to gravity and due to the short ligaments of the hips, depending on the species and age.

It seems likely that the shortness and tautness of the ligaments, which cause the physiologically reduced extension of the hip joint, also lead to a reduced abduction of the

same and that both movement restrictions are correlated to each other. The abduction possibility of the femora in the hip joints was therefore examined on 14 intact ligament-capsule-skeleton specimens. For this purpose, pelvises were fixed and adjusted on the subsurface in the aforementioned manner. The femurs were held so that the condyle axes were in the frontal plane, then bent into the sagittal plane to perpendicular to the longitudinal axis of the body and finally abducted until a springy resistance was felt. In this position, the angles were measured that the femoral longitudinal axes laterally formed with the flat subsurface.

The measurement results are recorded in the table after page 24. They show that with the research methods used that no femurs on any hip joints were abducted so far that their longitudinal axes came to rest in the frontal plane. The perpendicular bent femurs rather could only be abducted on average on the right side to 28.5 degrees and on the left side up to 29.0 degrees before the frontal plane. The abduction possibility, however, immediately increased as soon as the femurs were bent more than up to 90 degrees in the hip joints.



The graphic representation of the reduced stretching and abduction values found in the individual hip joints (fig. 15) shows that no regular relationships exist between the reduced stretching and abduction. The extent of the reduced abduction of the hip joints is therefore not determined by the state of the hip ligaments alone, but also by other factors, whereby likely the collodiaphys angle and the degree of ante-torsion of the coxal end of the femur also play a role.

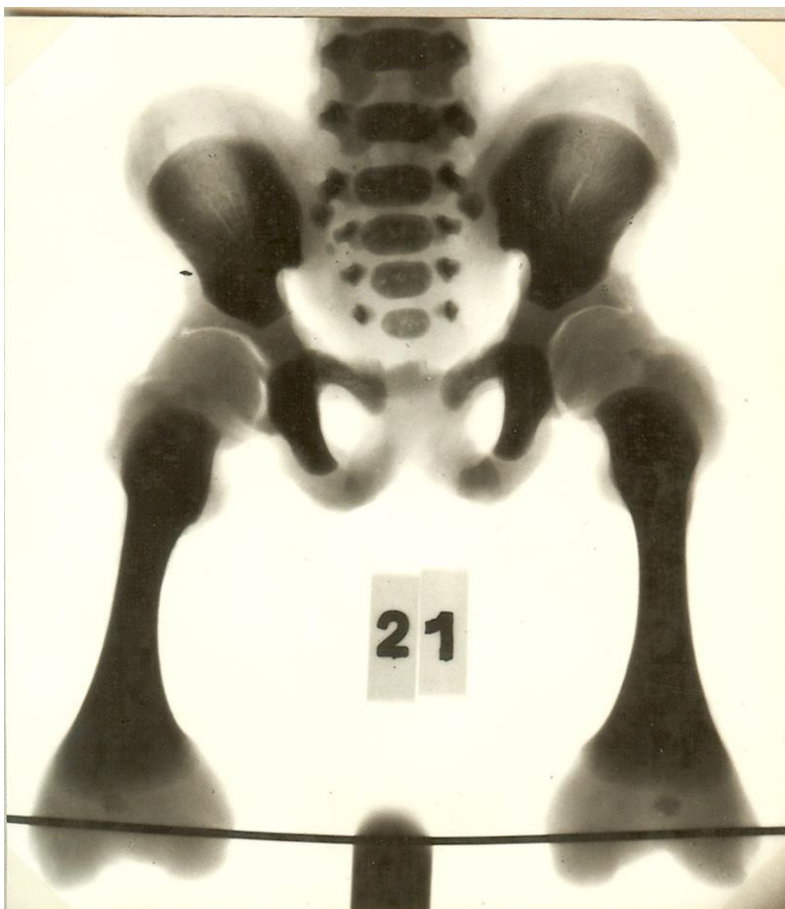The pelvic area of a 292-day old child with healthy hip joints studied outside of this series was already mentioned. There was no reduced extension of the hips on this child. The abduction of the femurs was, however, inhibited 24 degrees on the right and 26 degrees on the left in front of the frontal plane. SCHNELLE specifies the following for the living adult: the extension capability of the hip joint up to 180 degrees, the abduction capability of the leg at a perpendicular angle of 50-70 degrees, i.e. 40-20 degrees before the frontal plane. The assumption that the ligamentous-related physiological reduced extension of the hip joints of newborns is largely resolved within the first year of life, but that the restriction of the abduction capability of the bent legs resulting from various causes remains from birth on throughout life therefore seems justified.

The observation that the legs frequently can effortlessly abduct up to the frontal plane following prophylactic and therapeutic measures due to LH does not contradict this assumption. This excessive mobility has been acquired under unnatural conditions and also is lost again some time after completion of the spreading treatment.

Postnatal condition and development of the acetabulum

In addition to the studies of the capsule-ligament apparatus on the hip joint, the pelvises available were also examined with respect to the structure of the acetabulums. In particular, it was necessary to clarify the question as to whether the acetabulum of the newborn may be assimilated in functional significance to that of an ambulatory small child and adult or whether instead (similar to the behaviour of the anthropoids) it is adapted to the life of the child on the body of the mother.

The cartilaginous components of the hip joint body cannot be shown without special



technology in X-ray examinations of the pelvis of a living child. They have the same shadow density as those of the surrounding soft tissues and can therefore not be differentiated from these on the X-ray image. Using anthrography, the hip joint gap, i.e. the limitation of the femoral head and socket cavum, can be made visible. Fig. 16 shows the X-ray of the pelvic specimen of a mature, healthy child who died during birth. The air arthrogram of the hip joints represents the intra-articular conditions clearly. If the reference lines of

Abb. 16^a Das Luftarthrogramm der Hüftgelenke zeigt am Neugeborenenbecken eine scheinbar gute Überdachung der Femurköpfe.

HILGENREINER et. al. are used, it could be said of this image that the bony acetabular roofs developed according to age and cover the femoral heads well, and that the cranial cartilaginous socket portions shoot far beyond the femoral heads laterally.

Now it has long been known that the acetabulums of newborns are very shallow. Their depth is only 4/10 of the diameter (LE DAMANY). We also know that the sockets are arranged not precisely laterally, but rather in the ventral half of the pelvic ring so that the socket inlet plane forms an angle of 31 degrees with the sagittal plane (VON LANZ). Ultimately it must always be kept in mind that an X-ray deals with a projection, i.e. a kind of silhouette, of a three-dimensional body in a two-dimensional plane.

Considering this fact, the wide lateral overhanging bony and cartilaginous covering of the femoral heads in fig. 16 is only apparent. The socket inlet faces the view more. The hollow spherical sector is therefore projected obliquely on the X-ray film and therefore is shown larger than it is in reality. To make the distortion clear, X-rays were taken in various planes, after which the acetabula were filled in with an opacifying clay up to the

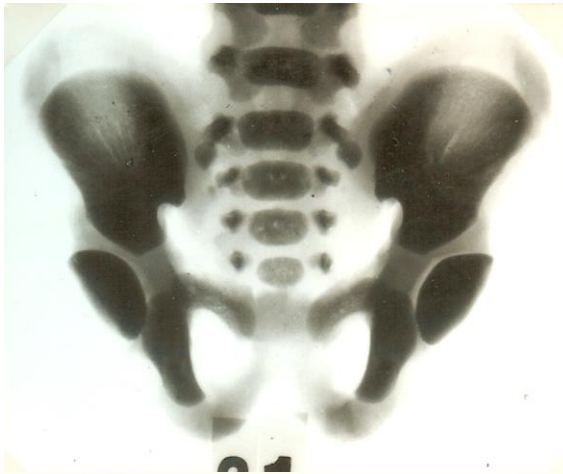

Abb. 16b Am gleichen Becken sind die Pfannen mit einer schattengebenden Knetmasse bis in Höhe der Pfanneneingangsebenen ausgefüllt. Durch deren Neigung zur Sagittalebene stellen sich die Acetabulumschatten fast als Halbkreise dar und täuschen eine größere Pfannentiefe vor, als sie in Wirklichkeit vorhanden ist.

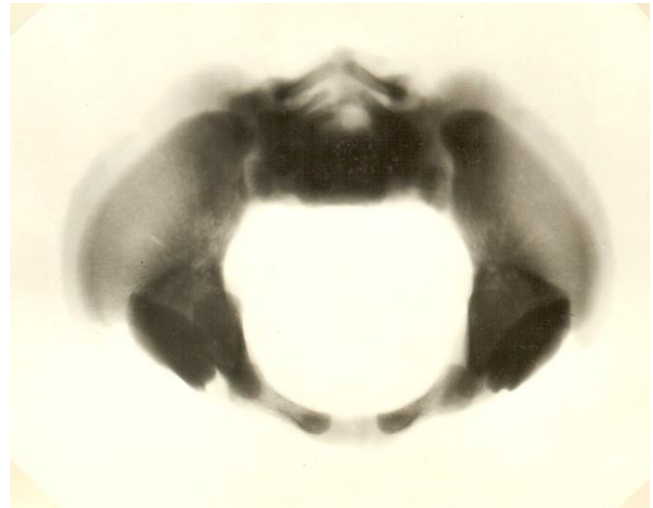
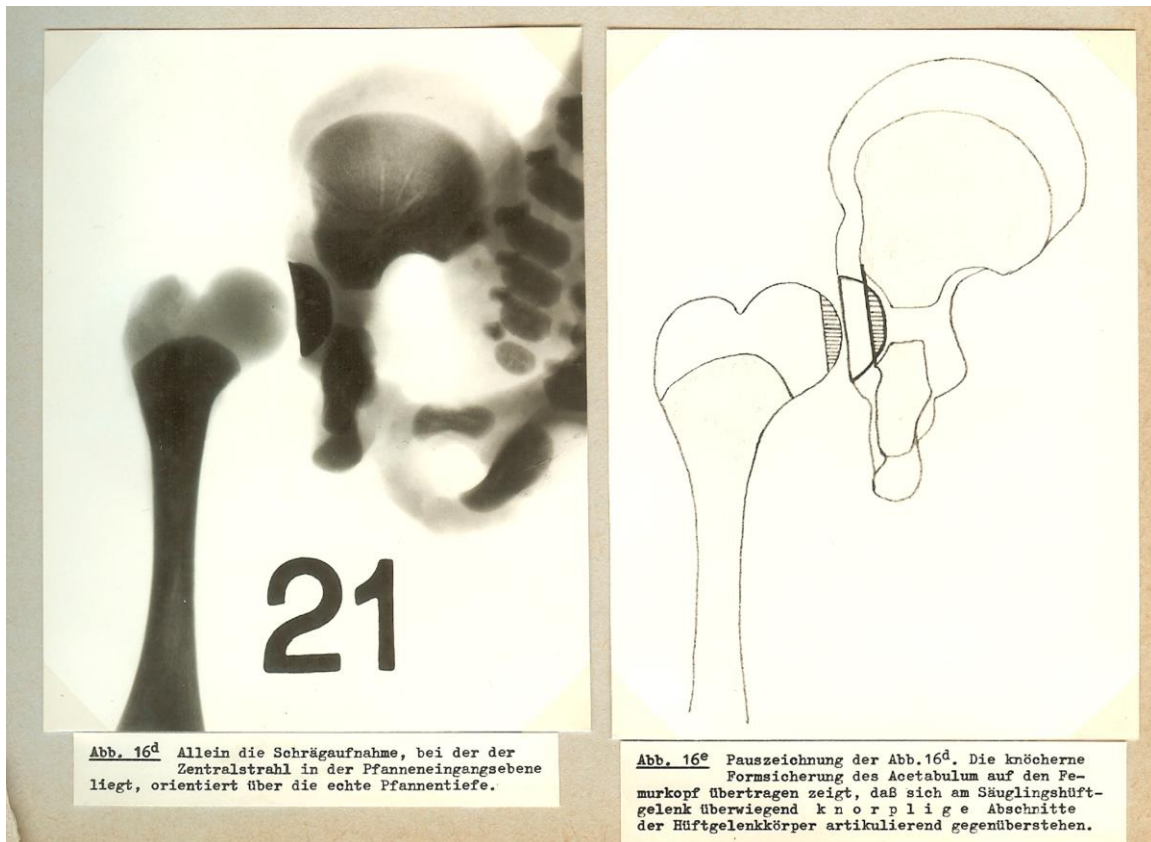


Abb. 16c Die Röntgenaufnahme in cranio-caudaler Strahlenrichtung läßt bereits besser die Flachheit der Hüftpfannen erkennen.

height of the socket inlet plane (edge of limbus) (fig. 16 b). In the image of a pelvis in such a way in a cranio-caudal direction of radiation (fig. 16 c) the flatness of the sockets can be seen much better than in fig. 16 b. However, this technology does not allow for the representation of the true socket depth, since the socket inlet plane runs from cranial-lateral to caudal-medial, i.e. not perpendicular to the image plane.

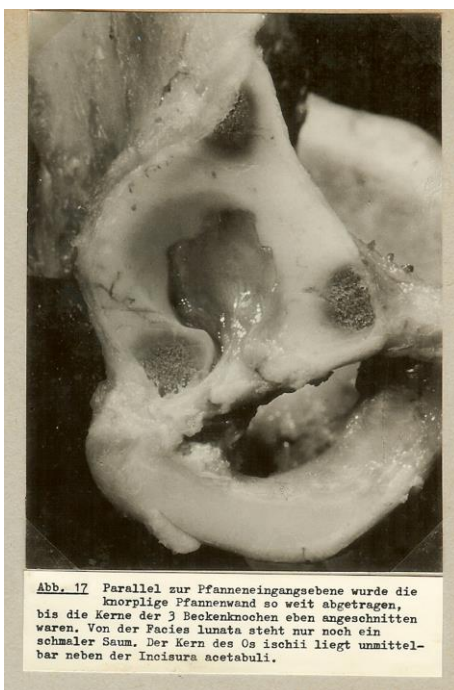Only the oblique view where the central beam lies exactly in the socket inlet plane (fig. 16 d) provides the accurate picture of the depth of the acetabulum. To avoid a distortion of the coxal femur end in the image, the associated femur was positioned next to the pelvis so that its femoral neck axis was parallel to the image plane. The age-appropriate antetorsion of the femoral neck was therefore compensated for. This image shows perfectly how little the newborn socket can cover the femoral head and how much the socket from the X-ray of the pelvis simulates a wide coverage of the head.



In other respects fig. 16 d is extraordinarily revealing, but shows that the shape securing of the acetabulum of the newborn is very minimal due to the three ossification centres of the ischium, pubic bone and ilium. Only the socket base and not even half of the quite shallow socket is surrounded by bone elements (fig. 16 e). If the form-secured part of the acetabulum is transferred to the femoral head, as happened in the drawing, then it can be seen that only a much smaller part of the head has a bony resistance in the acetabulum in the stretched position. In addition, a large part of the shaded drawn socket region of the Fossa acetabuli is recorded and therefore appears as a truly articulating surface.

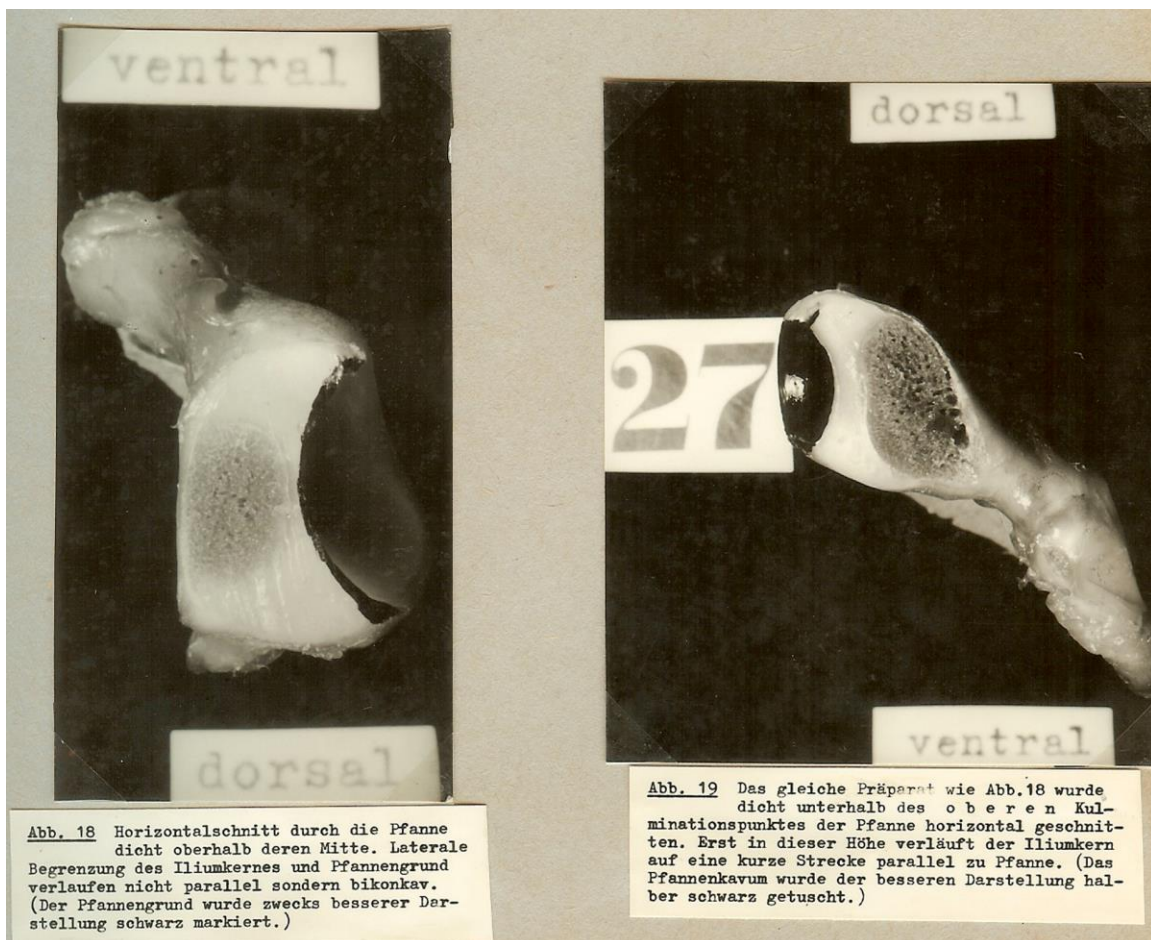
The vast majority of the newborn socket and almost the entire joint surface (used as a load-bearing zone in an upright position) consist of cartilage that, as already mentioned, is remarkably soft and malleable immediately after birth.

The predominantly cartilaginous property of the socket wall in newborns could also be proven by the fact that, from cuts parallel to the socket inlet plane, the cartilaginous components were carried as far as the cores of the three pelvic bones in the cut surface. If these were just cut, then usually only the Fossa acetabuli and a relatively narrow fringe of the Facies lunata were left of the acetabulum (fig. 17).



If the acetabulums of the newborn consist almost exclusively of cartilage and a bony support for the femoral heads is almost completely missing in the stretched position of the legs, then the usual conclusions about the "bony acetabulum" cannot be correct, which are made from the commonly used X-ray images. It was therefore necessary to study which form the ilium core has within the socket cartilage and how much of the ilium core is projected in the X-ray imaging as a free edge or as an "acetabular roof" on the film.

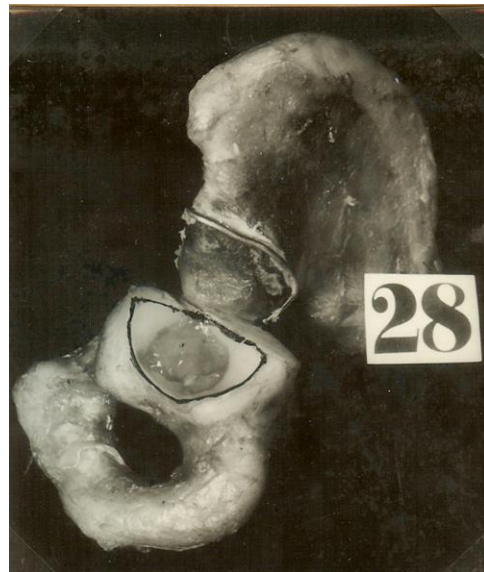ROHLEDERER dealt with similar problems. However, he performed his studies on the pelvis of a three-year old child, i.e. on a specimen, which no longer comes into question for the pathogenesis of the LH. Nevertheless, his results show that (for the X-ray diagnosis of the hip dislocation) "the so-called roof angle is not determined by the anatomical property of the roof, but rather by the shape of the bay and by the pelvic tilt".



After numerous preliminary investigations, an acetabulum was cut horizontally on specimen 27 slightly above its centre. It can be seen on the cut surface (fig. 18) that the ilium core does not run parallel to the cut edge of the socket in order to osseously secure its shape, but rather instead so that it is shaped too convex after the socket. The next closest section of the ilium core to the socket centre in newborns is therefore completely uninvolved in the shape retention of the acetabulum. Only in a more proximally placed cut level just below the cranial culmination point of the socket can a course of the ilium core (fig 19); the socket is coloured black for a better representation) be found on a short

section that is approximately parallel to the socket that can be suggested as a clear osseous form securing for the cartilaginous socket.

The shape of the Os ilium that is too convex after the socket cavum is first shown in full extension, however, after the upper half of the hip joint cartilage had been dissected from the ilium (fig. 20, the edges of the resulting lower socket halves were marked with black ink halfway for a better representation). The dorsal cartilage-bone border was ventrally marked with lead dust spots that were mixed with a quick-drying adhesive using an easily bendable wire. The X-ray image of this specimen (fig. 21) shows that the so-called "acetabular roof" is formed by the excessive convexity of the ilium core after the socket



cavum.

Abb. 20 Die obere Hälfte der Knorpelpfanne ist abgetragen; der Iliumkern liegt frei. Die dorsale Knorpel-Knochen-Grenze ist mit einem Draht, die ventrale mit Bleitupfen belegt. Die auf die Pfanne gerichtete Konvexität des Iliumkernes ist gut zu erkennen. (An der stehengebliebenen unteren Hälfte der Knorpelpfanne wurden die freien Ränder schwarz markiert)

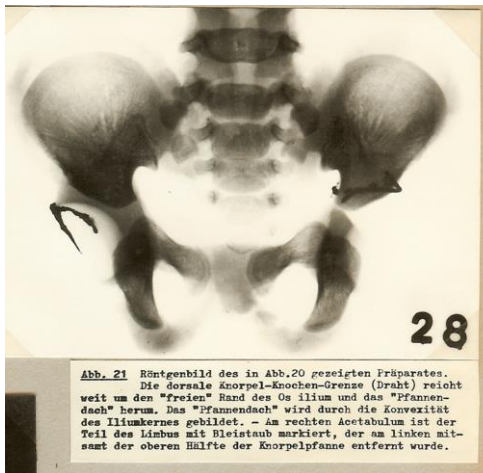

Abb. 21 Röntgenbild des in Abb. 20 gezeigten Präparates. Die dorsale Knorpel-Knochen-Grenze (Draht) reicht weit um den "freien" Rand des Os ilium und das "Pfannendach" herum. Das "Pfannendach" wird durch die Konvexität des Iliumkernes gebildet. - Im rechten Acetabulum ist der Teil des Ilium mit Bleistift markiert, der am linken mit einer der oberen Hälfte der Knorpelpfanne entfernt wurde.

(On the right acetabulum, part of the limb was marked with lead dust, which had been dissected from the left socket together with its socket cartilage for the purpose of showing the ilium core). The ilium core is, however, not uniformly convex to the socket.

The top view of the specimen from a more cranial direction (fig. 22) and in particular the X-ray image of the isolated pelvis halve (central beam in the plane of the cartilage-bone

border of the Os ilium) (fig. 23) show

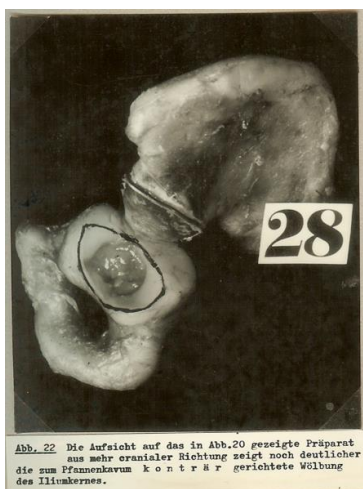

Abb. 22 Die Aufsicht auf das in Abb. 20 gezeigte Präparat aus mehr cranialer Richtung zeigt noch deutlicher die zum Pfannenknorpel konträr gerichtete Wölbung des Iliumkernes.

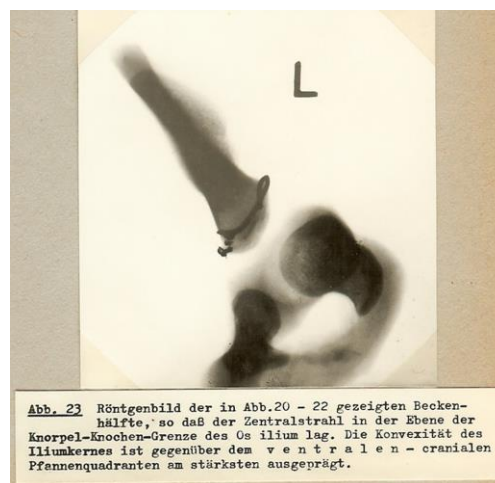
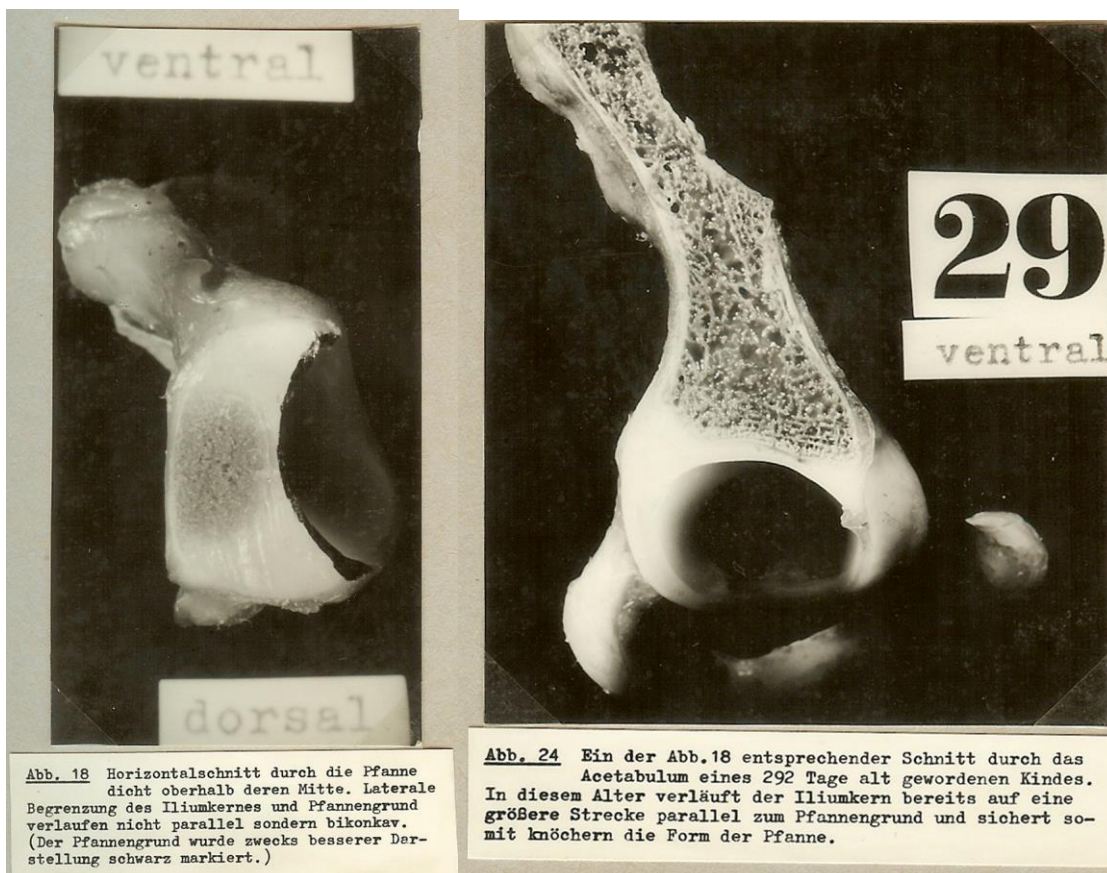


Abb. 23 Röntgenbild der in Abb. 20 - 22 gezeigten Beckenhälfte, so daß der Zentralstrahl in der Ebene der Knorpel-Knochen-Grenze des Os ilium lag. Die Konvexität des Iliumkernes ist gegenüber dem ventralen - cranialen Pfannenquadranten am stärksten ausgeprägt.

that the protrusion of the ilium is most pronounced opposite the front upper quadrant of the acetabulum. What we are call the "acetabular roof" on the normal X-ray image of the pelvis is therefore the open edge of the convexity of the ilium core that is opposite the front upper quadrant of the socket.

The ventral-cranial quarter of the acetabulum is, however, never the load-carrying zone for newborns with outstretched legs (as the studies on the hip joint ligaments have shown). Much more, this is in the dorsal-cranial socket area. It is thus in a section that is exclusively made of cartilage (which LUDLOFF already referenced in 1902) and whose shape in no way is secured in the depths from the osseous ilium core. Only in the course of the extra-uterine skeletal maturation does the convex shape of the ilium surface opposite the socket decrease in order to transition into a concave shape that runs more parallel to the socket cavum and to therefore also osseously support the rear-upper quadrant of the acetabulum, as shown by a corresponding cut (fig. 18) on a specimen of the 292-day old child (fig. 24).



The "radiographical acetabular roof" or the so-called "roof angle" therefore do not say anything directly about the property of the load-bearing zone of the acetabulum in the newborn and infant. The cores of the three bones that form the socket first approach the acetabulum near the end of the intra-uterine foetal time (LUDLOFF) and first grow into the cartilaginous socket wall postnatally. The size and shape of the ossification centres depend on the state of maturity of the skeleton for all bones. The radiographical acetabular roof must be shorter and steeper the more immature the os ilium is. The "acetabular roofs" shown in the X-ray image and their angles do not correspond to the load-bearing sections of the socket in newborns. However, they are of great diagnostic

value, because they allow indirect conclusions about the state of maturation of the acetabulums.

FABER found too steep of an acetabular roof angle in 15 newborns, but two months later the angle had normalised in 13 of the studied children without treatment. In these 13 newborns, the state of maturity of the hip joints did not correspond to the foetal age and only postnatally did it achieve the normal angular values of the "acetabular roofs" due to accelerated skeletal maturation. The X-ray diagnosis of "dysplasia", which refers to the erroneous (by no means always leading to luxation) conditioning of the hip joint (PITZEN), pathologically and anatomically relates to a true immaturity of the ilium core based on the age of the child examined. The fact that not only the ilium, but rather the entire functional unit of the "hip joint" is to be regarded as immature in such cases cannot be proven using the X-ray image, but must be logically concluded from other observations. The assumption is however permitted that such an immaturity of the hip joint in any case goes hand-in-hand with an abnormal flatness of the cartilaginous socket and therefore a readiness for luxation would exist. Such a readiness for luxation would only be seen in the fact that the cartilaginous wall on the immature hip joint is softer and therefore more easily deformed by pathological pressure than at a state of maturity appropriate to the age.

For this reason, the acetabulum of the newborn and infant cannot be equated in functional importance with that of the older child and adult, because its wall is composed almost exclusively of soft, easily deformed cartilage. Only in the 2nd year of life does the consistency of the cartilage increase so that it is then grown more to the task of bearing loads, especially because at this age the cores of the three pelvic bones come closer to the socket and support the maintenance of their shape.

The X-ray examination of the infant pelvis

The radiographical representation of the acetabular roof and its assessment is not yet carried out according to a standardised technique. In numerous publications (PITZEN, ROHLEDERER, SCHLEGEL and many others), it is referred to that the roof angle depends on the degree of the pelvic tilting during the X-ray photograph. My own examinations confirm this. It has not been attempted enough previously to standardise the X-ray examination of the pelvises of newborns and infants so that the X-ray results are accurately evaluated, especially so that X-ray images from various institutes can be assessed according to uniform guidelines. More often, an expedient positioning of the legs during the X-ray photographing has been referred to (M.E. MÜLLER, PITZEN, BÜSCHELBERER). However, criteria are missing that make it possible to accurately determine just from the X-ray images whether the child has been correctly or incorrectly positioned during the examination.

The examinations of the hip joint ligaments have shown that, in the 1st year of life, a physiologically reduced extension of the hip joints exists in varying degrees, on average 43 degrees. In general, the legs are secured parallel during the X-ray photograph with kneecaps facing forward using a belt or manually on the bucky table. Previously, the lower leg was allowed to hang over the end of the table. The position of the pelvis is only paid attention to so that it is not tilted sideways due to muscular defence. The

unphysiological lumbar lordosis of the spine and the forwards tilting of the pelvis, which occurs due to the age-appropriate reduced extension of the hip joints when pressing the upper leg onto the flat surface, are usually ignored. The radiographic representation of the acetabular roof angle is therefore not only dependent on the state of maturation of the ilium core, but rather also by the degree of physiological reduced extension of the hip joint

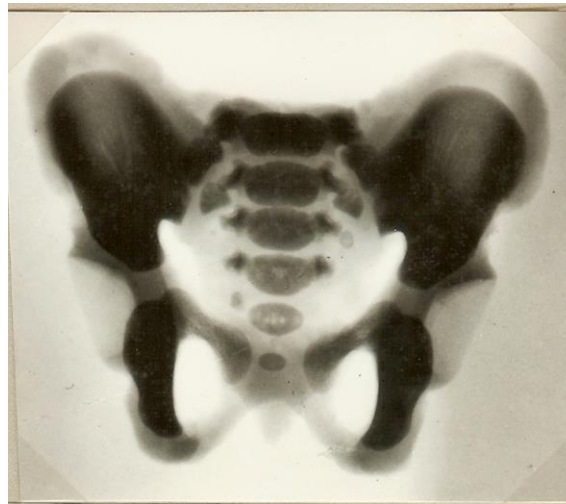


Abb. 25 Zwischen Iliumkern und Pfannenkvum projiziert sich im Röntgenbild bei richtiger Lagerung des Beckens eine breite Knorpelschicht.

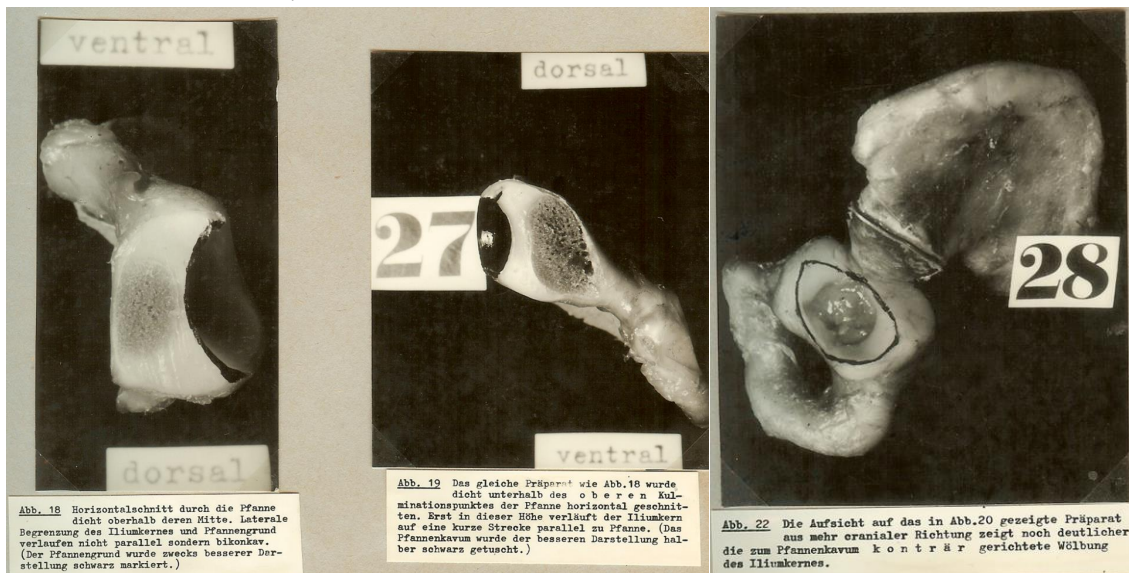


Abb. 18 Horizontalschnitt durch die Pfanne dicht oberhalb deren Mitte. Laterale Begrenzung des Iliumkernes und Pfannengrund verlaufen nicht parallel sondern bikonkav. (Der Pfannengrund wurde zwecks besserer Darstellung schwarz markiert.)

Abb. 19 Das gleiche Präparat wie Abb.18 wurde dicht unterhalb des oberen Kulminationspunktes der Pfanne horizontal geschnitten. Erst in dieser Höhe verläuft der Iliumkern auf eine kurze Strecke parallel zu Pfanne. (Das Pfannenkvum wurde der besseren Darstellung halber schwarz getuschelt.)

Abb. 22 Die Aufsicht auf das in Abb.20 gezeigte Präparat aus mehr cranialer Richtung zeigt noch deutlicher die zum Pfannenkvum k o n t r ä r gerichtete Wölbung des Iliumkernes.

Fig. 25 shows the correct positioning of the pelvis so that a thick layer of cartilage can be seen between the ilium core and the socket cavum, as can also be seen in the anatomical specimens (fig. 18, 19, 22). The arthography of the right hip joint in fig. 26 a (only a little air was injected so as not to push the joint body apart) shows the same. With this specimen, the physiological reduced extension on the right hip joint was 47 degrees and on the left hip joint was 49 degrees. The femurs, which were connected by a Kirschner wire in the condyle axis, were therefore positioned raised by about 50 degrees for the X-ray photograph. If the femur longitudinal axes only formed an angle of 25 degrees with the film cassette, then the pelvis was also tilted forwards by about 25 degrees and on the

X-ray photograph (fig. 26 b) the contrast shadow of the hip joint gap truncates the ilium core evenly. The acetabular roof angles are shown to be smaller than in fig. 26 a. In a third X-ray photograph, if the femurs are positioned parallel to the film plane and the pelvis is then tilted by nearly 50 degrees ventrally, then the contrast shadows are projected into the ilium core and there is a further reduction of the roof angle, an overlap of the bone cores in the Y-joints as well as a strong distortion of the pelvic skeleton (fig. 26 c).

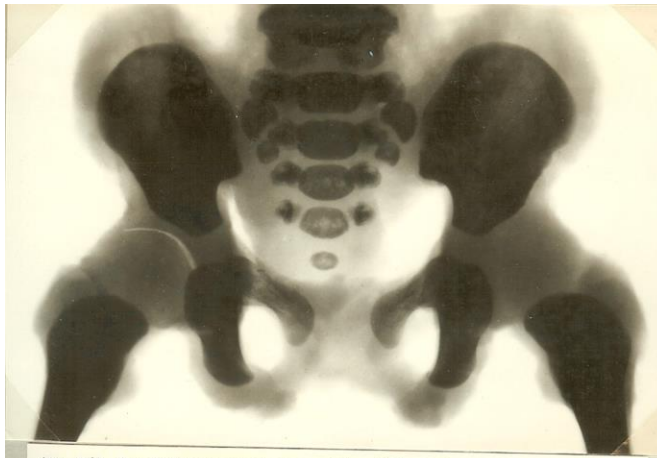

Abb. 26^a Das Luftarthrogramm des rechten Hüftgelenkes zeigt die gleichen Verhältnisse wie Abb. 25. Das Becken wurde also bei der Röntgenuntersuchung richtig gelagert, d.h., weil eine Streckhemmung der Femora von 47° bzw. 49° vorlag, mit um etwa 50° angehobenen Femora.

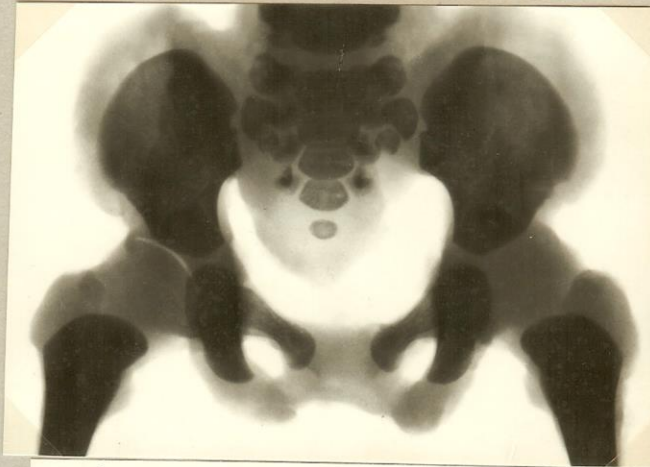

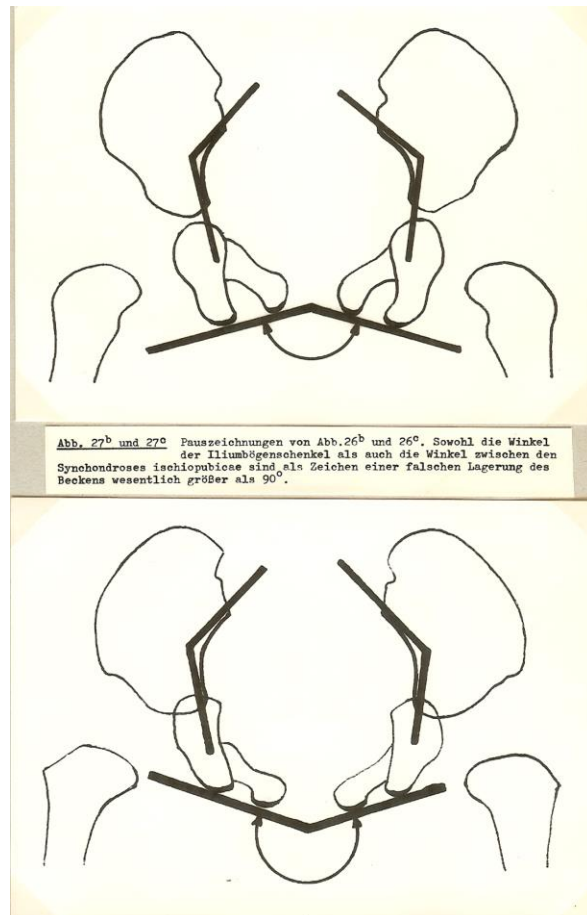
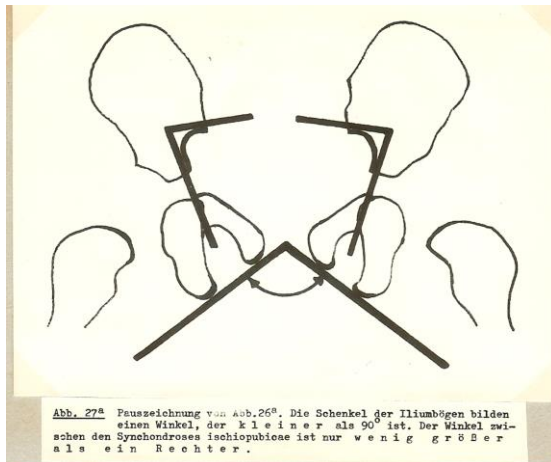
Abb. 26^b Das gleiche Becken wurde um etwa 25° nach vorn gekippt. Der durch Luftfüllung dargestellte rechte Hüftgelenkspalt schneidet den Iliumkern eben an. Die Lagerung des Beckens bei der Röntgenuntersuchung war also falsch!

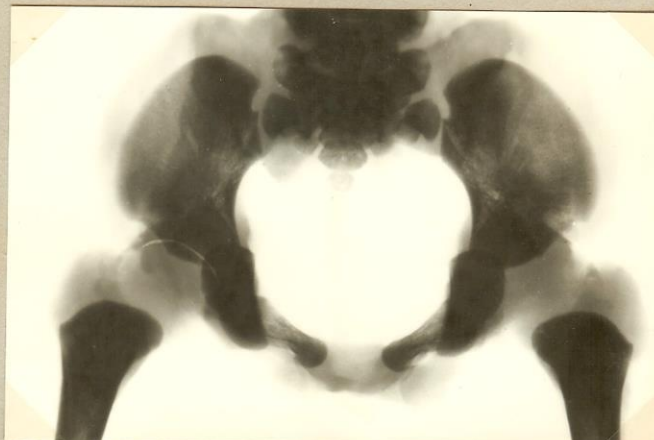

Abb. 26^c Wird das Becken entsprechend der Streckhemmung der Hüftgelenke um etwa 50° nach ventral gekippt, dann projiziert sich der Hüftgelenkspalt in den Iliumkern bzw. das "Pfannendaak" in den Femurkopf hinein. Die Lagerung des Beckens war zur Beurteilung des Reifezustandes der Hüftgelenke also noch schlechter als in Abb. 26^b.

The acetabular roof angle is therefore reduced by tilting the pelvis forwards so that the convexity of the ilium surface opposite the socket cavum is ventrally stronger than it is dorsally.

If the three X-ray photographs of the same pelvis are studied in various tilted positions (fig. 26 a-c) and significant representations of existing shapes are sought after that even inexperienced persons would recognise immediately, then one's attention is drawn to the Partes ilicas of the Linea terminalis (linea arcuatae ossium ilium) and the synchondroses ischiopubicae. The Linea terminalis is shown in the area of the ilium as an arc that is flatter the more the pelvis is tilted forward. If the wings of the ilium arc form a 45-90 degree angle, then the pelvis was properly positioned during the X-ray to show the hip joints and the "acetabular roofs" (fig. 27 a). If the angle is larger than a correct angle, then this is evidence of a ventral pelvic tilting (fig. 27 b and 27 c). If the medial border of the bone cores of the pubic bones and ischium are combined on both sides, then these form a nearly 90 degree caudal open angle (fig. 27 a). If this angle is significantly larger than a right angle (fig. 27 b) or even exceeds 180 degrees (fig. 27 c), then this is also evidence that the pelvis was tilted forwards and therefore was also incorrectly positioned for the assessment of the hip joints.



The figure of the ilium arc and the angle between the synchondroses ischiopubicae were checked on numerous X-ray photographs of children's pelvises and their value was repeatedly confirmed for the comparability of X-ray photographs.

For daily practice, it is to be demanded from these observations that X-ray examinations of the pelvis of newborns, infants and small children are to be performed with the hip joints bent. The hip flexion must correspond to the degree of physiological reduced extension. This is larger in a newborn than in a small child. For an exact positioning, it is

useful to use positioning wedges made of radiolucent material with various sized rise angles for the thighs and a perpendicular fall for the lower leg.

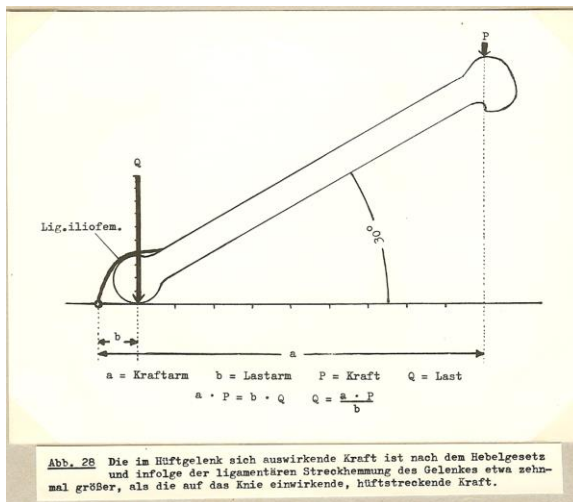
One certain disadvantage of this photographing technique is the projection-induced distortion of the coxal femoral end, in particular the head core for older infants and small children. The X-ray diagnosis of LH, however, is primarily interested in the "acetabular roof" and the position of the coxal femoral end with respect to the Y-joints. Both are represented in the best possible way with this technique, which is recognisable by the fact that there is no distortion on the normal pelvis within the known guidelines according to SHENTON and CALVE. If, however, the shape and the antetorsion of the femoral neck as well as the collodiaphyse angle are to be assessed and determined more closely, then the described X-ray technique is not shown. For such cases, the femurs must be positioned in a plane parallel to the film cassette.

The functional and mechanical significance of the physiologically reduced extension of the hip joints and the "circuitous development" of the hip joint body

Civilisation and other influences have separated mother from child and made a "bed infant" out of the "breast infant" (PEIPER). Immediately after birth, the newborn is wrapped in swaddling clothes and rolled tightly in a wraparound garment, which reaches from the nipples to over the feet and is folded there so that the child is virtually stuck in a tight bag with its trunk and legs. Usually a heavier than not blanket or duvet is then put on this packaging and "kicking blanket" is sometimes tightened over the child. Therefore everything is done to curtail the urge to move the legs as much as possible and to make the newborn into a "homo erectus" as quickly as possible (OMBREDANNE cit. acc. FRISCHKNECHT).

Such a forced extension of the legs that is continuously acting on the infant during the first months of life impedes the resistance of the physiologically shortened ligament apparatus of the hip joints, in particular the medial leg of the unyielding BERTINI ligaments. This cannot always remain without impacting the sockets.

Together with the Pars medialis, of the Lig. iliofemorale, the femur forms a unilateral lever whose fulcrum lies on the Tuberculum ilicum, the small field of origin of the BERTINI ligament (fig. 28). The power arm of the lever extends from the Tuberculum



ilicum to the femoral condyles. Its load arm extends from the fulcrum to the femoral head. The ratio of the power arm to the load arm behaves somewhat 10:1 on the pelvis and femur of the newborn. According to the lever principle, a force acting on the femoral condyles that stretches the hip joints must press the femoral head against the socket wall with ten-times the force. If it is assumed that the wraparound garment and blanket press on the knee joint with just a weight of 100 grammes, then a pressure of 1 kilogramme must be calculated within the hip joint.

If we now examine what section of the acetabulum has to absorb this pressing of the femoral head, then the reinforcing ligaments of the hip joint capsule must be referred to again. The task of the Pars lateralis of the Lig. iliofemorale as an extra-articular protective organ for the cranial socket section has already been explained. The femoral head is pressed against the intra-articular surface of this ligament side, especially against its dorsal edge. Further dorsally, between the Pars lateralis of the BERTINI ligament and the cranial edge of the Lig. ischiocapsulare, is a triangular thin point of the joint capsule

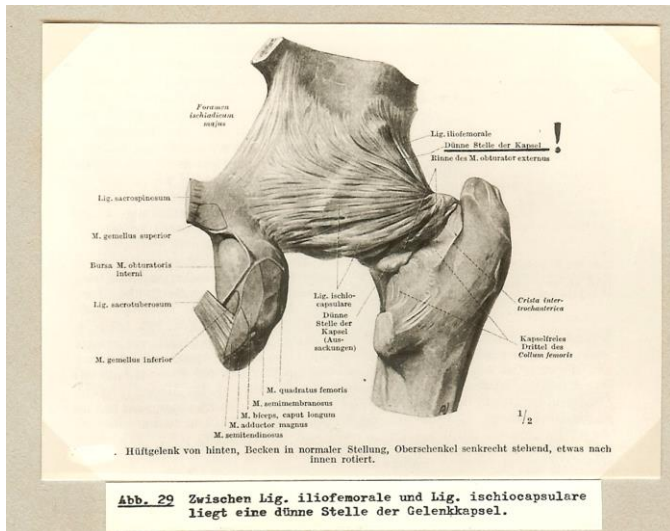


Abb. 29 Zwischen Lig. iliofemorale und Lig. ischiocapsulare liegt eine dünne Stelle der Gelenkkapsel.

(fig. 29), which is not traversed by any reinforcing ligament. "There is also the fact that this part of the rear cartilaginous edge of the socket is very low" (LUDLOFF). The pressing of the femoral head therefore occurs against the rear-upper socket quadrant (fig. 30), which in no way is prepared for this use of force and therefore is a predilection site for the formation of a luxation path (fig. 31). LUDLOFF is also of the opinion that with the LH "the head sought its path behind the Lig. iliofemorale superius" (in

current nomenclature: Pars lateralis of the Lig. iliofemorale).

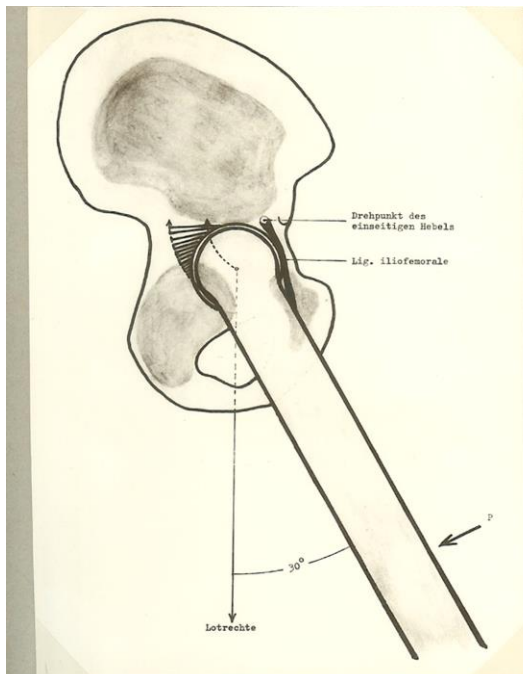


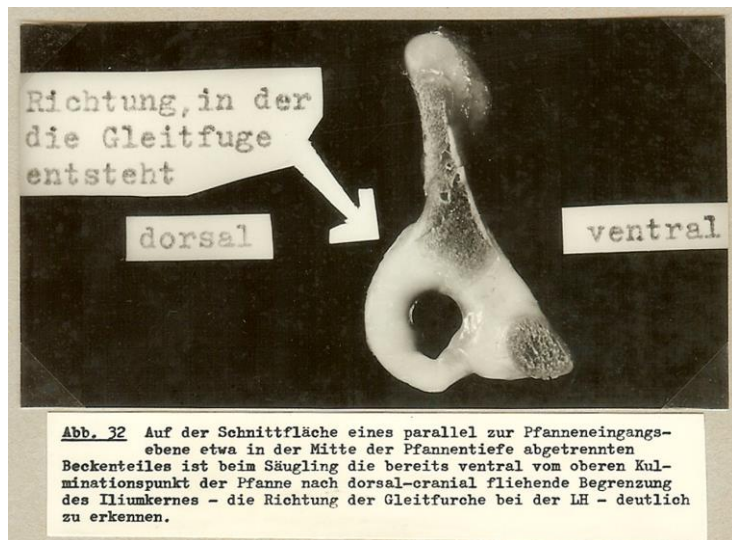
Abb. 30 Der hintere-obere Pfannenquadrant wird infolge der beim Säugling physiologischen unnachgiebigen Verkürzung des Lig. iliofemorale bei Streckung des Hüftgelenkes überlastet.

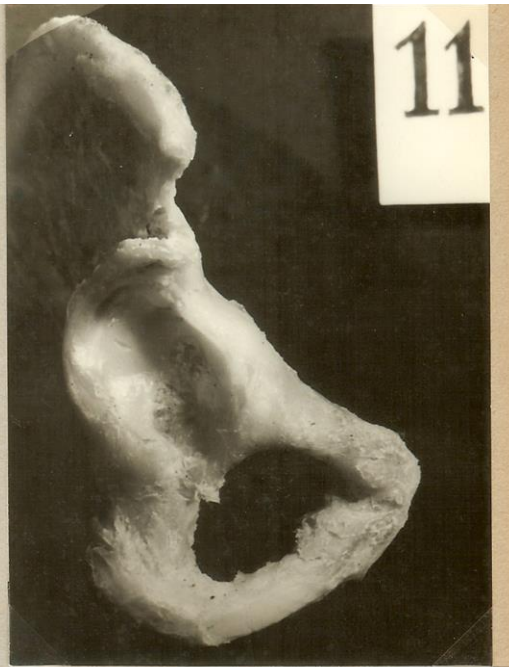

Abb. 31 Bei der Luxationshüfte hat der Femurkopf im hinteren-oberen Pfannenquadranten den Limbus und die knorpelige Pfannenwand niedergewalzt und sich damit dort einen Luxationsweg erzwingen.

If the pelvic apparatus is cut parallel to the socket inlet plane roughly in the middle and the cut surface of the separated piece (fig. 32) is considered, then one can again see the ilium core that is already steeply running ventrally from the upper culmination point of the socket to the upper-rear and the exclusively cartilaginous property of the dorsal socket wall. The sliding furrow that the femoral head digs into the

rear-upper quadrant of the socket wall during the LH runs parallel to the dorsal limitation of the ilium core, i.e. in the rearward leg of the Y-cartilage. LUDLOFF comes to a similar result based on his pelvic studies. But he believes that with the innate hip luxation, the femoral head already leaves the socket in the foetal life while the examinations represented here show that the LH is related to the non-observance of the physiologically reduced extension of the hip joints of newborns in common infant care in civilised countries.



All previously described investigations led to results from which it can be concluded that the hip joints of newborns do not have any structures, both with respect to their composition as well as in terms of their range of motion, that are made for walking upright. However, they mature into such structures within the 1st year of life, i.e. in the time that PORTMANN describes as the extra-uterine foetal time.

Observations of anthropoids, the remarks by PEIPER about the intimate relationship of the child to the mother and the known fact that among many peoples the mothers constantly carry their children around with them suggest that the hip joints of the newborn are exclusively adapted to a life of the child on the body of the mother.



Two types of carrying newborns, infants and small children prevail among the still largely natural living tribes of people: carrying on the hip (fig. 33) and tying the child to the back of the mother (fig. 34). With both methods, the children have their legs bent in the hip joints by more than 90 degrees and are excessively abducted. The spine here has a slight total kyphosis and the pelvis is more dorsally tilted than ventrally. In fig. 35 (if the perspective distortion is ignored), the approximate abduction angle of the legs can be measured with respect to the sagittal plane. It is 43 degrees on the right and 39 degrees on the left. However, it will likely be somewhat larger, since the femoral longitudinal axes do not run parallel to the shown soft part contours of the thigh.

If the pelvis-femur specimens are examined in this flexion-abduction position, then (unlike the aforementioned studies with the stretched position of the femurs) it can be seen that the hip joint capsules and their reinforcing ligaments are largely relaxed. The extra-articular hip ligaments run on the stretched leg dorsally and ventrally in the same direction helically around the femoral neck (fig. 36 and 29).

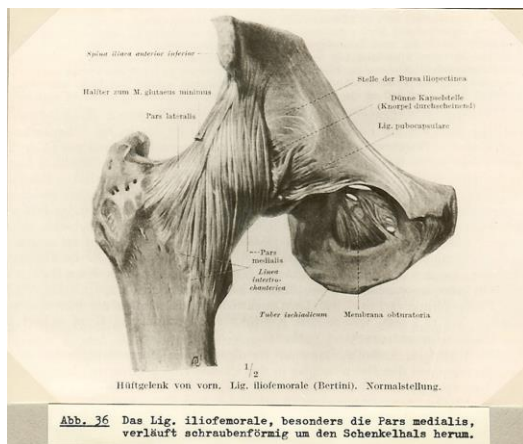


Abb. 36 Das Lig. iliofemorale, besonders die Pars medialis, verläuft schraubenförmig um den Schenkelhals herum.

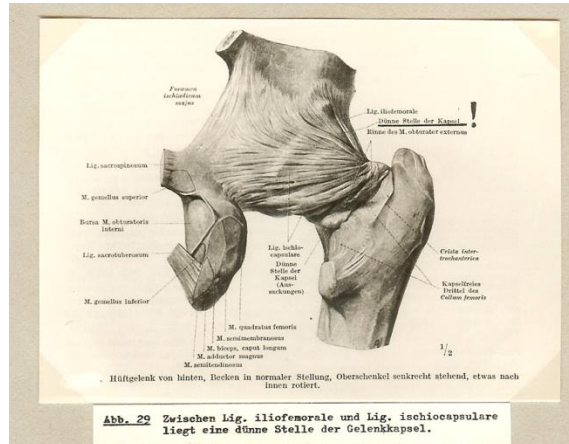


Abb. 29 Zwischen Lig. iliofemorale und Lig. ischiofemorale liegt eine dünne Stelle der Gelenkkapsel.

The bending and the abduction of the leg releases the helical winding and the ligaments take a more linear course between the origin and onset. The intra-articular Lig. teres femoris also relaxes in the flexion-abduction position, because then (as already was stated above) the groove running from the Fovea cap femoris head ligament is covered with the Incisura acetabuli.

The relaxation of the hip ligaments is a very crucial factor for the nourishment of the femoral head, because the collum vessels run through the hip joint capsule and a blood supply for the femoral head occurs through the Lig. teres from the A. acetabularis. In connection with the youthful hip head solution, IMHÄUSER drew attention to the danger of the avascular femoral head necrosis by "screwing down" the hip joint ligament apparatus.

The angle of impact of the femoral neck axis on the socket inlet plane is of crucial importance for the further maturation of the hip joints. VON LANZ pointed out that "this angle of impact may be construed as a numerical expression of the utilisation of the individual joint sections". A perpendicular irradiation of the femoral neck axis in the socket inlet plane would therefore mean that the femoral head stresses all socket sections

evenly, which is considered an ideal case for the maturation and structural shaping of the hip joint, which LE DAMANY already went into detail about.

Now the studies on the pelvic specimens showed that bending the femurs by about 110 degrees and the simultaneous abduction by about 40 degrees in fact causes the femoral neck axes to be almost perpendicular to the socket inlet planes. The position of the legs that is required to position the femoral neck axes perpendicular to the socket inlet plane is of course dependent on the size of the collodiaphyse angle, the position of the socket within the pelvic ring and perhaps on the degree of antetorsion of the coxal femoral end. The relationships of these three factors for the position of the leg in the three-dimensional space cannot be visually represented flawlessly. This can be made clear on the pelvic specimen, but even better on deformable socket and femoral models made from clay.

In order to make the child's life on the body of the mother possible in the manner shown on figs. 34 and 33, the child must be able to effortlessly spread its bent legs so that the insides of the thighs rest on the mother's body. The younger the child is, the narrower its



Abb. 34 Masai-Frau am Manyarasee (Ostafrika) mit Kind auf dem Rücken



Abb. 33 Südamerikanische Indianerin vom Xingú mit Kind auf der Hüfte

legs are, i.e. the smaller the distance of the child's hip joints to each other. A newborn would therefore have to spread its legs further than an older child in order to find intimate contact with the mother. But this is not necessary! Due to the angular position of the femoral neck to the femoral longitudinal axis, a stronger bending of the legs can increase the distance between the medial femoral condyle without changing the vertical position of the collum axis of the socket inlet plane. A strong flexion of the legs is not an unusual unphysiological position for the

newborn, because the lower extremities are fixed in an extreme flexed position at the end of intrauterine life. The collodiaphyse angles largely determine the distance between the right and left medial femoral condyle for the perpendicular position of the femoral neck axes. The larger the femoral neck shaft angles are, the wider the spread position of the bent femurs is and the less the thighs need to be flexed in order to achieve a condyle spacing that is just as wide as with the lesser angular degrees.

The position of the socket or the socket inlet plane within the pelvic ring (at an incident angle of the hip joint of 90 degrees) also co-determines the extent of the spread position of the flexed femurs. If the socket inlet plane is more sagittal, then the abduction point of the thigh will be larger than with the more frontal arrangement.

The direction of the socket inlet plane and the extent of the collodiaphyse angle together almost exclusively determine the degree of the flexion and abduction point of the thigh, which is necessary for the femoral neck axis to vertically meet the socket inlet.

The so-called antetorsion of the femoral neck likely plays a minor or perhaps no role at all for the extent of the flexion and abduction of the leg required for the centring of the femoral neck axis. However, it plays a very important but different role that can be particularly well illustrated using the mouldable model. Using the femur made of plasticine, if the femoral neck axis is brought into the same plane as the condyle axis (antetorsion = 0 degrees) and the femoral neck is put vertical to the socket inlet plane in a flexed position, then the condyle axis has moved considerably close to the direction of the body's longitudinal axis. This means that the lower legs of the child would have come across the front of the body or, if carried on the mother's hips, almost horizontally on its stomach and back, a position in which they can find no support. Fig. 53 contains the condyle axis of the child approximately in the horizontal plane so that the flexed lower legs can dangle without force. The same position of the condyle axis is obtained if the femoral shaft is retro-torqued by 30 - 40 degrees from the last described position on the mouldable femur model.

Here the so-called antetorsion of the coxal femoral end would have the task in the child's life of ensuring a relaxed posture of the lower leg on the mother's body without the impact angle of the hip joint deviating from the perpendicular angle. For such functional mechanical stresses, it

would therefore be more correct not to speak of an antetorsion of the femoral neck, but rather of a retro-torsion of the entire major femoral section located below the trochanter. In practical work, however, the designation "antetorsion of the coxal femoral end" must be maintained, because in later life the condyle axis sets in the frontal plane and then the femoral neck is rotated in front of this plane.

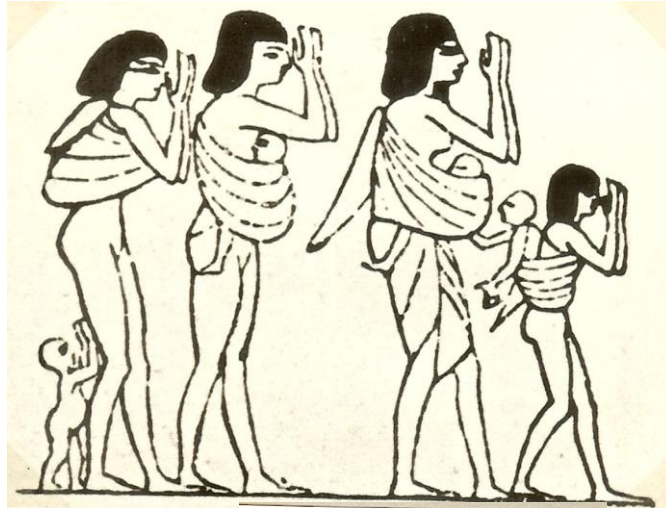


Abb. 53 Altägyptische Klageweiber mit Kindern auf ihrem Körper

The close physical togetherness of mother and child makes it possible to view the intra and extra-uterine shape changes of the hip joint in another light than has been previously shown. NAUCK calls such design and positional changes "circuitous development processes", because "these changes occur between two identical or very similar conditions, since the initial and final behaviour correspond to each other". The socket inlet plane, femoral neck angle and femoral tension initially develop in a straight line from the early embryonic form to the final state. "Near the end of pregnancy, the shape development moves away from this straight path quickly and sharply accentuated. The indices move away from those of the adult form. After birth, the disruptive influences seem to disappear. The development again moves into the original direction and now runs uniformly until the adult final shapes" (VON LANZ).

According to VON LANZ, the inclination angle of the socket inlet plane to the sagittal plane is 39 degrees in the 4th embryonic month, increases to 51 degrees by the 8th embryonic month, goes back to 31 degrees by birth in order to then enlarge again to 42 degrees post-natally to adult age. The femoral neck angle steadily decreases by the 9th

embryonic month, but increases in the 10th embryonic month and even considerably in the 1st and 2nd years of life in order to then slowly lower to the adult dimension after the 3rd year of life. In intra-uterine life, the development of the femoral torsion does not experience any withdrawal. However, at the time of birth it reaches almost three times the state of the final adult stage, remains at almost the same value in the 1st year of life and only in the 3rd year of life the regression of the strong torsion sets in relatively quickly.

Just like certain reflexes and reactions that have been found on newborns intra-uterine, but already fully formed, which must be viewed as species-specified and inherited expedencies for preserving the individual, the circuitous development processes on the hip joints can be viewed as an adaptation of the child to life on the body of the mother. The sagittal position of the socket inlet planes predominant at birth and the enlarged femoral neck angle expand the spreading ability of the flexed legs without the impact



Abb. 37 Naxsi-Frau mit g e h f a h i g e m Kinde auf dem Rücken (Ostafrika)



Abb. 38 Assamesen-Kinder in Indien



Abb. 39 Kinder aus dem Bergvolke der Kurubas im Staate Mysore / Indien



Abb. 40 Assamesischer Junge mit Bruder auf dem Markt in Jaziranga (Indien)

angle of the hip joints greatly differing from a right angle. The inclination of the socket inlet plane to the sagittal plane does decrease already in the 1st year of life, but as compensation the collodiaphyse angle also increases post-natally.

The third year of life first brings the final break with the circuitous development of the hip joints, an age when the child has become a truly perfect biped and a safe upright walking person with versatile independent relationships to its near and far environment.

In primitive peoples, mothers and older siblings still then frequently carry children on their hips or the back long after they have been able to walk (fig. 37 and 38). Children then often assume a more stretched position of the leg (fig. 39 and 40). Even independent anthropoid children often climb on the backs of the mother, hold themselves securely in the fur of the mother animal with bent and spread legs and are thus carried around. The life of the child on the mother's body therefore does not suddenly end once

learning to walk freely. The child is slowly weaned of this life, which means a load in increasing doses for the hip joints.

LE DEMANY sees "gross anatomical errors" in the "forward askew acetabulum" and in the torsion of the femur, which cause the "so-called innate hip joint dislocation as a necessary consequence" when the opposite extreme variants come together. Also according to VON LANZ there "a meeting of these extreme variants appears to favour the occurrence of congenital hip dislocation". Such conclusions are not only of theoretical, but also of the utmost practical importance for the care of newborns and infants. The "errors" do not lie in the anatomy of the hip joint, however, but rather in the

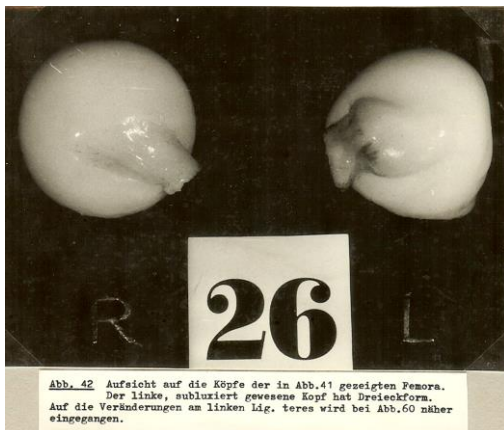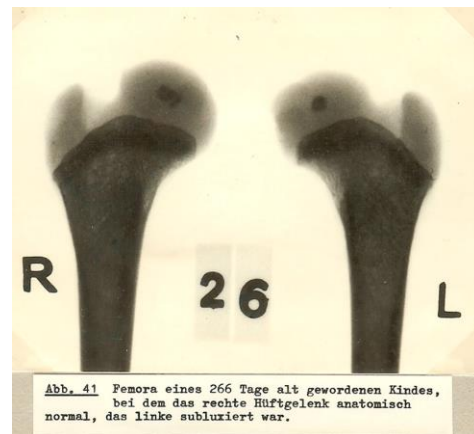way in which the child's legs are constrained in an unphysiological position with swaddling cloths during the 1st year of life. For the child's life on the mother's body, the "gross anatomical errors" instead prove to be the most meaningful forms of adaptation! Even the meeting of extreme opposite variants on the socket and femoral neck cannot adversely effect such a life, because the child's position on the mother's body varies frequently and greatly. Due to the movements of the child and the mother, the impact angle of the hip joint changes. The femoral neck axis moves within a right circular cone, whose axis is the perpendicular to the socket inlet plane and whose apex lies in the pivotal point (centre of the sphere) of the femoral head. In this way, all sections of the femoral head and acetabulum are evenly stressed, which is of crucial importance for their normal development and the prevention of LH.

Application of the theory of PAUWELS regarding the differentiation of the supporting tissue on the formation of deformities in hip luxation

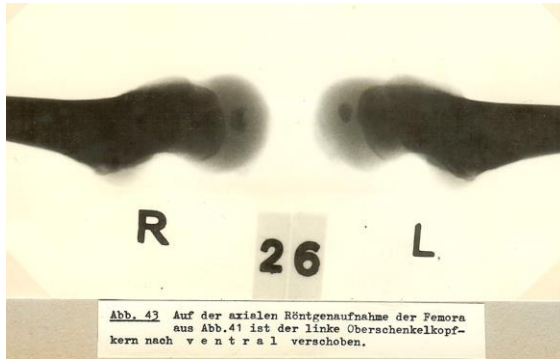
The studies by PAUWELS have shown that the bone core of the upper femoral epiphysis forms where pure hydrostatic pressure acts, because "at places of pure and high hydrostatic compression stress the cartilage is calcified after maximum swelling of the cells and is replaced by bone tissue".

The best conditions for the development of the femoral head core therefore exist if all areas of the femoral head are evenly stressed. This is the case in an infant in the physiological flexion-abduction position of the legs, because only in the infant does the impact angle of the hip joint move approximately around a right.

However, if the femoral head is displaced from its central location in the acetabulum, for example from subluxation, then the compressive stresses in the head reduce and the compressive and tension trajectories change their directions so that the "repulsive singular point" (PAUWELS), the formation location of the bone core, is shifted. The reduction and shifting of the compressive stresses are partly responsible for the femoral head being smaller on the LH side than on the healthy side, for the fact that it



deforms and also for the fact that the epiphysis core forms later. Fig. 41 shows the femur of a 266-day old child who had a right hip joint that was healthy but whose left hip joint was subluxated. x) In the X-ray photograph, the femoral neck axes were placed parallel to the image plane. The left femoral head and its core are much smaller than on the right specimen. The medial buckling of the contour is simulated by the Lig. teres. In the view, you can clearly see the more triangular shape of the left femoral head (fig. 42).

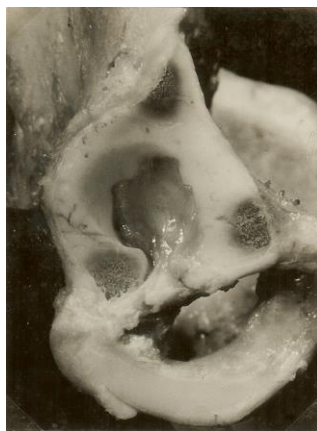

such a new formation of bones in the cartilaginous epiphysis would not be possible in the first place. The socket does not come into question as a ventrally situated pressure field, because its opening faces the front-side. In addition, the extended leg with LH is known to rotate outward so that the ante-torqued head is directed forward to a strong degree. The ventral pressure field is generated by the two legs of the Lig. iliofemorale, which, together with the rear-upper socket wall, clamp the femoral head when the leg is extended. The physiological shortening of the Lig. BERTINI is therefore not only of importance for the formation of the luxation path in the cranial-dorsal socket quadrant, but also for the faulty development of the femoral head, which leads to the known Dogenhut shape of the head core in the older luxated child.

^{x)} I would like to thank Prof. Dr. Dr. HARNAPP, Director of the Children's Hospital of the Medical Academy of Dresden, and Dr. med. HAFERLAND, Commercial Director of the Pathology Institute of the Medical Academy of Dresden, for the friendly relinquishment of this specimen.

The theory inaugurated by PAUWELS regarding the influence of the mechanical stimuli on the differentiation of the supporting tissues also explains the postnatal maturation of the acetabulum and the absence of this maturation process in the event of LH.

If all areas of the acetabulum are evenly stressed through the perpendicular position of the coxal femoral end on the socket inlet plane, then the cores of the 3 pelvic bones enlarge within the 1st year of life so that a deformation of the hollow body is prevented, even if the impact angle changes. If, however, the rear-upper socket quadrant is overloaded from the continuous stretching of the legs against the infant's physiologically



reduced extension of the hip joint, then the other quadrants will be relieved. As fig. 17 shows, however, this contains the 3 bone cores of the acetabulum of the next quadrant. Due to the absorption of the hydrostatic pressure in the vicinity of these ossification centres, the stimulus for the calcification and ossification of the chondrocytes disappears. The bone cores remain behind in their development and are therefore immature with respect to the age of the child. In the cranial-dorsal socket quadrant, as was portrayed by the studies of the hip ligaments, the cartilaginous wall gives in to the increased pressure. This results in compression and shear forces to stretch the tissue. According to PAUWELS, "stretching is a mechanical stimulus to which the cells and the intercellular substance surrounding them must react with the formation of

collagen fibrils". In areas where the hydrostatic compression is superimposed by intermittent shear force, i.e. the cells suffer a minimum intermittent distortion (i.e. a kind of "flexing"), they remain relatively small. The cartilage here shows all of the properties of growing young cartilage with an abundant basic structure and cell proliferation". These processes can also be verified in the histological findings of BERNBECK of the acetabular roof region with LH. He describes "severe mechanical damage to the chondral tissue:

fibrous degeneration, so-called "unmasking" of the fibrils that are normally invisible in the "hyaline" matrix", the "lack of typical "orders of columns" of the ossification stripes, striking cellular polymorphism, disorders of the basal cartilage calcification".

The long-known susceptibility of the rear-upper socket quadrant has a biological explanation in the directional change of the mechanical stimuli acting on the joint body and the different reactions of the tissue to stretching and hydrostatic pressure. It does not require the assumption that the acetabular roof is a phylogenetic new acquisition and therefore is not yet secure enough to make the occurrence of LH understandable. Quite the contrary! The hip joint is assumed to have such sufficient safeguards that LH only occurs relatively seldom, even though with primitive peoples all infants have to spend their life in a "bed that is an unnatural environment" for them (PEIPER).

Clinical signs of the dysplastic hip joint and its relationships with metabolic disorders

Even if "the human child, who has involuntarily become the "bed infant", has not developed any new adjustments to the bed" (PEIPER), then it would be incorrect to see the cause for the occurrence of LH in the unphysiological method of our childcare alone. The appointed studies have indeed shown that prolonged stretching of the hip joints against their physiological reduced extension can mechanically initiate the luxation process in infants, and that it inevitably leads to hypoplasia, deformation and relative immaturity of the joint body so that eventually the luxation of the hip joint develops due to mechanical and biological laws. However, other factors must be involved in the pathogenesis of the LH, because otherwise a far higher percentage of children who spend their infancy in bed would be afflicted with LH.

For uniform functional reasons, such pathogenetic factors must be sought after both at the joint bodies themselves as well as at the neuromuscular elements of the hip joint.

According to JAROS, often (up to 30%) of congenital dislocations and other deviations occur in children not carried to term than with children carried to term. "Frequently (21%) they occur accompanied by other deformations and errors, which also have the character of a developmental delay" (JAROS). The same author cites SOMMERVILLE, who calls dysplasia a "persistent foetal alignment of the hip". The foetal character of the hip joint area is characterised by a lack of bone core development around the acetabulum and the already described softness of the cartilaginous socket wall. The shape of the socket is not changed with dysplasia, the preliminary stage of subluxation and luxation. If changes in shape of the acetabulum were found in fetuses and newborns, these are likely to be construed either as a persistence of the early embryonic egg shape of the hip joint body or would have to be attributed to the real teratological hip dislocation. It is known from numerous observations that there is initially no interruption of the SHENTON line in the X-ray "socket arm", i.e. no displacement of the femur cranially, but that such a

dislocation may occur within the first months of life. This means that even in children with hip dysplasia the femoral head is in a normal rounded acetabulum immediately after birth, which is first expanded postnatally.

In many newborns and very young infants with, as the other development showed, healthy hip joints, the sliding movement could be detected, which PITZEN again drew attention to in 1949 as a sign of the start of luxation. Even on my own pelvic specimens, it could be found and was all the more evident the more immature the development state of the newborn was. Pushing and pulling could move the femurs in the longitudinal direction, resulting in a deformation of the socket wall. Always with compression in the cranial direction, the socket window was sucked in under the Lig. transversum acetabuli due to the intra-articular vacuum and the pull of the Lig. teres to the socket. Conversely, the fat pad there was pressed out of the socket window when the femur was pulled on.

The sliding movement therefore shows the yielding of the cartilaginous socket wall in the first weeks of life. The easier it is to perform, the softer and more immature the cartilaginous socket is. Radiographically, this can be proven with 2 photographs, which PITZEN has shown. In older infants, however, where the X-ray image already shows an interruption of the SHENTON line without a forced posture of the legs, the sliding may indicate a deformation of the acetabulum.

HILGENREINER, SCHEDE, PITZEN, etc. have referred to the dislocation and reduction sound as a sure symptom of LH. The study method is described as follows: the leg is flexed at an acute angle in the hip joint and adducted and then compressed longitudinally. The dislocation sound occurs here. The reduction sound occurs for the abduction of the leg. Without a doubt, a subluxated femoral head has occasionally been dislocated and reset without anaesthesia. It is only very rare that the femoral head is subluxated in newborns and in the first weeks of life. My own studies of hip-healthy pelvises have shown on the individual specimens, when the described methods were used, the flawless snap phenomena without a luxation occurring. The snapping occurred much more by the fact that the groove of the femoral head, which runs from the Fovea capitis to the equator, slid jerkily onto the rear-lower socket edge, so that the head came into a subluxation position. The same phenomenon could be triggered with the moderate flexion, adduction and inward rotation on the rear socket edge. With the soft cartilage sockets, the snapping occurred more easily than on mature specimens so that it can also be viewed as a sign of the hip joint immaturity in the first weeks of life.

The causes of the dysplastic immaturity of the hip joint in newborns, which otherwise have normal signs of maturity, have been much discussed. "Dysplastic joint systems are quite common in infant hips. The hip joint is so-to-say not done at birth. It catches up on the final development readily, however, in many cases (23%)". (BECKER). According to PITZEN, the development of dysplasia depends on the degree of the biological value of the joint, which has geographic variations. NAGURA sees this as a successor stage after intra-uterine luxation and also prenatal spontaneous reposition. It is known that heredity is assumed as the cause of dysplasia in 20% (ISIGKEIT) to 42% (LE DEMANY). In our own patients, it is striking that relatively frequently mothers of luxation children specify having suffered from severe morning sickness for months. Changes to metabolism, especially the vitamin balance, are triggered by this. JAROS insistently refers to the

specific meaning of the vitamin D group for the development of the mesenchyme and especially the bones and to the role of vitamin B deficiency in teratogenesis. He writes: "A lack of vitamin B does not have to cause any visible changes in the mother, but rather it suffices in causing a developmental delay (in the child). It can be suspected that a developmental delay arises from a dampening effect on the fermentation processes in the growing tissues and by the reduction of the glycogen levels in the growing and proliferating chondrocytes and apparently in mesenchyme cells". According to research by the "Institute for People's Nutrition in the CSSR [Czechoslovak Socialist Republic] and according to SABATA, the vitamin B deficiency in humans, and especially in pregnant women, is not covered by a normal diet. EHRENBURG points out that vitamin B1 is required for optimal calcium absorption. An inadequate supply of this vitamin could therefore lead to an ossification disruption in the sense of hip dysplasia.

In a very interesting paper "On the question of exogenous origin of congenital malformations", WOLFF discusses the nutritional lack of the mother as a teratogenic factor in the child. Contrary to a popular belief, he writes: "The embryo may suffer from the nutritional deficiency more than the mother. The embryo does not always get what it needs, but instead the mother keeps most of the nutrients for itself". In connection with the lack of vitamins in the diet, he refers to animal experiments where a lack of vitamin B and D in the feed of the mother animals led to skeletal and cartilaginous malformations in the young. He concludes from this: "It is certain that a lack of certain substances in the mother's diet can lead to certain embryonic damage".

In the same sense, the writings of KROMPECHER and NAGURA can be interpreted to mean that children born in the winter months suffer from LH 2.5 times more frequently than those born in the summer, because without a doubt the vitamin needs of the body are not met as well in the cold seasons than in the warm seasons. NAGURA's view that the movement impediment of the legs from the tighter wrapping of children in the winter causes the accumulation of LH during this time should therefore not be rejected under any circumstances. Both together, the lack of vitamins and the tight wrapping of the children in cold months, are very likely responsible for this increase.

Regarding the hormone metabolic disorders, it is particularly the diabetes mellitus of mothers that can very frequently lead to malformations in their children (IDELBERGER). Sometimes a larvate diabetes, which is only manifest during pregnancy can therefore often remains undetected, but by means of hypoxemia leads to hip dysplasia, can simulate a heritability of hip trouble. Many other endogenous and exogenous ways also lead to the disruption of the embryogenesis so that the same image, the dysplasia of the hip joint in the form of delayed bone core development around the acetabulum and the softness of the cartilaginous socket wall, can occur in varying degrees. The susceptibility of the acetabulum is therefore dependent on the state of maturity of the hip joint area based on the postnatal age of the child.

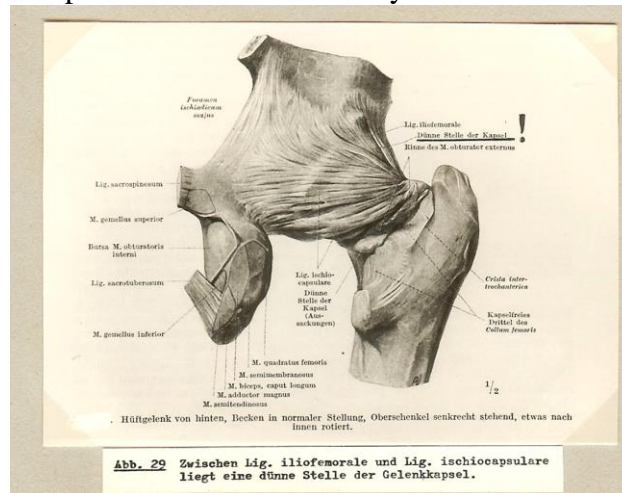
The physiological and pathological hypertension of the muscles as a pathogenic factor of hip luxation

It is known from the LH clinic that the gradually luxating leg assumes an outward rotating position that already comes to hypertension of the adductors beforehand, from which a real contracture of this muscle group can develop over the course of the

suffering. For the complete hip dislocation that exists for a long time, it is not just the adductors, but also the ischiocrural muscles that are shortened. This is recognisable by the well-known phenomenon that a resilient resistance exists when stretching the knee joint according to the traditional reposition in the LORENZ position.

The spasticity of the adductor group can act in a damaging manner on the hip joint in three ways with a simultaneous stretching of the leg:

- 1.) By abducting the leg, the femoral head is cranially considerably rotated out of the acetabulum. The Pars lateralis of the Lig. iliofemorale, however, does not permit a stronger adduction upon the further possible stretched position of the leg and, together with the medial leg of the BERTINI ligament, pushes the femoral head dorsally into the gap between the Lig. iliofemorale and the Lig. ischiocapsulars (fig. 29). This displacement is reinforced by the fact that



- 2.) the adductors have a outward spinning effect with the legs outstretched. With the outwards rotation of the leg, the ante-torqued coxal femoral end is pressed even more greatly in an intra-articular fashion against the unyielding BERTINI ligament than by the leg extension alone. This counterpressure leads to the displacement of the femoral head after the rear-upper socket quadrant and therefore to its overloading.
- 3.) The hypertension and especially the contracture of the adductor group not only lead to the adduction and outward rotation of the leg, but also have a cranially-directed, longitudinally compressive effect on the extended leg. With a muscular contracture, the origin and onset of the muscle approach each other permanently. The adductors originate on the pelvis and insert at the femoral shaft. Both fixed points can only approach each other in the stretched position if the femoral shaft moves cranially, which is possible from the displacement of the femoral head from the acetabulum. (The reverse, the reposition from shortening the femoral shaft with a constant contraction of the adductors, is performed with the well-known operation according to LOEFFLER-ZAHRADNICEK.)

The cranial-dorsal socket section is therefore not pressed by the unphysiological extension of the legs common with our childcare, but also by the effects of a hypertension

of the spreading musculature. A deformation of this section in the sense of LH may occur at the dysplastic acetabulum.

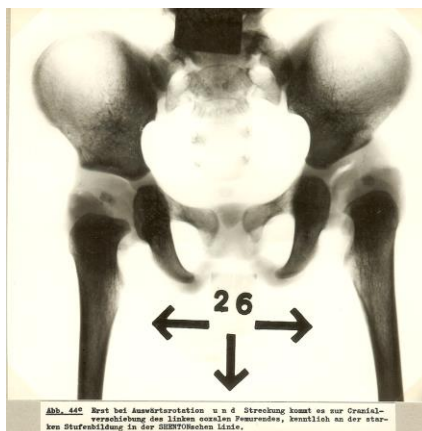
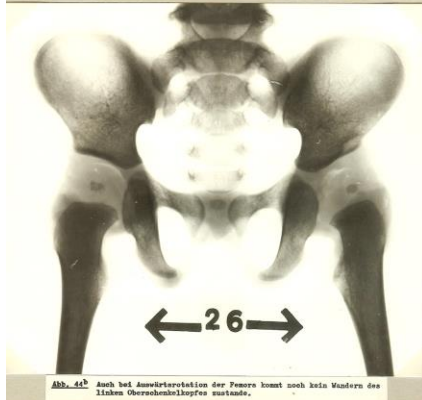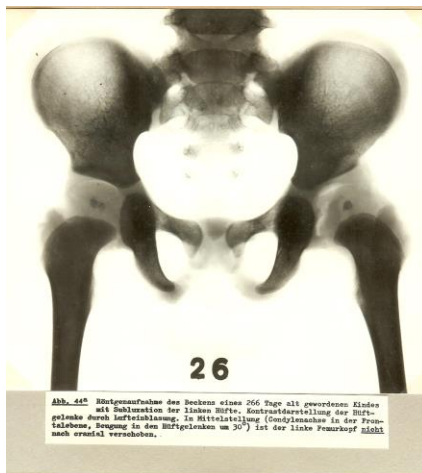


Fig 44 a - 44 c very clearly show the effect of stretching on the outward rotated leg. These X-ray photographs show the pelvis of a 266-day old child with a left-sided subluxation. (Both hip joints were filled with some air to mark the joint gaps.) Fig. 44 a is a "normal picture" where the condyle axes in the frontal plane and the femurs (according to the right-side reduced extension) were held raised by about 30 degrees. In fig. 44 b, the femurs were rotated outward in the same flexed position. Both images show that the left femoral head apex is slightly apart from the socket and the SHENTON line is slightly interrupted thereby. But the femur is not cranially displaced either in the central position or due to the outward rotation of the femur, because both femoral neck apices are at exactly the same height. If the outwards rotated femur, however, is stretched with a weight of 200 g, then the left coxal femoral end moves upward to a great degree, which can be seen by the significant interruption of the SHENTON line. The outwards spinning component of the adductor hypertension exacerbates the injurious effect of the unphysiological hip stretching at the rear-upper socket quadrant and both forces together cause the formation of the sliding furrow and the movement of the femoral head.

It is important both for the pathogenesis and for the treatment of LH to search for possible causes of hypertension of the adductor group.

While in newborns the musculature is developed relatively poorly, their tonus however often increases considerably and never falls below a certain degree under normal conditions, even at a later infancy age (JOPPICH). In addition to this hypertension (measured by the extent of an adult) of the entire musculature of the infant, a "stronger tonus of the

adductors is singular to the first period of life" (PEIPER). The crossover of the legs during the crying movements as a result of increased innervation of the adductors is, as PEIPER describes, "quite characteristic for newborns who otherwise lay there often with crossed legs".

Since the musculature is atonic immediately after birth, but the hypertension develops in the first days of life, HARRIS, LIPSCOMB and HODGSON studied 11,010 children on the 1st and 5th days of life and thereafter at regular intervals for their ability to spread their legs. They found that after the newborn period an abduction ability of the perpendicular bent legs of 90 degrees is no longer common. In the 3rd quarter of the year,

the legs can be spread by 60 - 70 degrees. For dysplastic and dislocated hips, the abduction was limited to 45 - 60 degrees. A positive "abduction test" would exist if the abduction was only possible up to 60 degrees or less, which was to be an inducement for an X-ray of the hips.

The striking hypertension, especially of the adductor group, at the infant age can be viewed as a tonic reflex, since it is known that the rigor of the spreading muscles goes away under anaesthesia, provided a real contracture has not already developed. Such a tonic reflex of the adductors would be regarded as an adaptation of the child to life on the mother's body. Similar to a fixed leg closure that connects the horse with the rider, the child holds onto the mother's body using its adductor hypertension.

The effects of the adductor hypertension on the hip link are extraordinarily revealing. The power development of a muscle is larger the more its fibres are stretched. In the spread position of the legs, as they are shown, when the mother carries the child on her hip or back, the child's adductors are in a permanently stretched state and can therefore perform their task under the best conditions.

The knee joints of the child find support on the mother's body so that an abducting force occurs at the distal femoral end that is equivalent to an adductor force. Applying the physical laws of forces and levers, it is seen that the adducting and abducting forces act on the proximal femoral end so that this is compressed into the acetabulum. Since the impact angle of the hip joint pivots by 90 degrees in the position described, the insertion of the femoral head in the acetabulum increases the hydrostatic pressure in the joint bodies, which promotes ossification, i.e. maturation, of the joint, as already described by PAUWELS. The physiological hypertension of the adductors is not only used in the living child to mechanically hold onto the mother's body, but is also biologically used for the further differentiation of the supporting tissue or to prepare the hip joints for their later function of carrying the load of the body.

If the infant's legs are brought into the stretched position, then the hypertension of the adductors work as it were "in the void", because the distal femoral ends do not meet any resistance and therefore no abducting forces can occur there. In this way, the quite typical crossing of the legs comes about in newborns that was described by PEIPER. At the proximal femoral end, the force compressing the socket inlet plane vertically goes away so that the further maturation of the hip joint may be delayed. In the stretched position, the origin and onset of the adductors are approached permanently, which is why the hypertension of this muscle group is capable of causing a true contracture of the same. It was already described above how an adductor contracture damages the hip joint, especially when an LH occurs.

The studies by HARRIS, LIPSCOMB and HODGSON as well as my own observations on numerous infants showed that the reflexive hypertension of the adductors may have different intensities within normal limits and sometimes may even be unequal on different sides. It is therefore quite conceivable that, under certain conditions, the idling of a pronounced, but still physiological hypertension of the adductors may lead to a double-sided or also unilateral LH. However, it is likely that a pathological increase of the adductor tonus plays a role in the occurrence of LH.

The adductors appear to take a special position in the skeletal muscles in the course of diseases not only in children, but also in adults. They are often hypertonic while the rest of the muscles have hypotension. We find this, for example, with chronic states of hunger and with osteomalacia of all kinds. The latter also includes rachitis (which has by no means become rare despite prophylaxis) where it is known that the smooth and striated muscles become hypertonic while the adductors alone can exhibit an increased spasticity.

Some other pathological disorders lead to a general increase of the muscle tone in infants, where usually the hypertension of the adductors is particularly striking.

For example, malnourished damage causes a significant muscle hypertension (KLEINSCHMIDT). Tonus and reaction changes of the muscles are also described with different vitamin deficiencies. The large field of neurological diseases, which can also lead to a hyperactivity of the abnormal muscles and then sometimes to LH, can be disregarded in studies on the pathogenesis of LH, which is occurring with alarming frequency. Such disorders are relatively rare, but usually are associated with such striking symptoms that their etiological connection with hip suffering can hardly be overlooked.

In summary it is to be noted:

The degree of maturation of the newborn hip joint varies. It is common at birth that the area of the acetabulum is still in a foetal development stage, which is characterised anatomically by deficient ossification of the 3rd pelvic bone and softness of the cartilaginous socket wall, and characterised radiographically by a "steep" acetabular roof and clinically characterised by displaceability and subluxatability of the femur. Exogenous and endogenous pathological changes in the mother, especially metabolic disorders, are often discussed as causes of dysplastic immaturity, provided it is not a premature infant and therefore ipso facto an immature child.

Shortly after birth, the child develops a hypertension of the adductors, which is necessary as a tonic reflex for the close physical coexistence of the child and mother and the most rapid maturation of the hip joint into the bearing organ. With the "bed infant" (PEIPER), there is an idling of this reflex, which can be further increased by pathological disorders in the child. Pathologically increased hypertension of the adductors and unphysiological stretching of the legs are capable of overloading a dysplastic, insufficiently matured hip joint, to deteriorate the development conditions of the hip joint body and to therefore mechanically and biologically initiate LH.

Hip luxation and traditional customs

The heritability of LH is very often discussed in literature. In 20 - 42% of the cases, a familiar predisposition is assumed, whereby the Caucasian race is particularly dispositioned to this suffering, much more rare is the Asian race and extremely rare is the African American (LE DAMANY)

According to LE DAMANY, no case of LH could be found in studies of 40,000 Sudanese. VIANNA reports from the orthopaedic clinic in Rio de Janeiro that among 10,000 patients of all races and regions of the country only 10 had LH, of which 8 were Caucasian. In Sao Paulo and Santa Catharina, the numerical ratios were somewhat

higher, but here too it was predominantly children of European immigrants who had to be treated for LH (cit. acc. to MOHING). In the northern states of the USA, LH can often be found. In Norway, according to NISSEN it could be found only in the north and northeast of the country, but relatively often in the mixed population of Finnmarks consisting of Laplanders and Norwegians (MOHING).

The racial mixture is very often blamed for the occurrence of LH, because on the one hand so-called "luxation clusters" often coincide with mixed racial areas, and on the other hand areas with racially uniform population structures often only have a few people afflicted with LH. This observation induced KAISER to write: "For islanders where a racial mixture has hardly occurred, such as among the Japanese, only very few cases of hip luxation are observed".

KAISER, however, is refuted by a Japanese person himself, by NAGURA. NAGURA tells of TASHIRO, who worked as a surgeon in Tokyo for twelve years and in 1900 came to Europe on a longer study tour. HOFFA asked him whether LH existed in Japan, which TASHIRO said no to, because he had never seen such a case in his practice in Tokyo. "However, as he then returned to Japan in 1904, gradually he saw cases of LH, contrary to expectations. And today we Japanese orthopaedists see cases of LH in our country just as frequently as in Europe and North America" (NAGURA) Around the turn of the century, the civilisation of life according to the European model set in rapidly. As NAGURA emphasizes, more and more ancient folk customs thus stopped being used, infants and babies were only carried on the backs of the mother or nurse and children frequently were left to crawl around on their stomachs in the living room furnished with little furniture, but with a soft clean flooring.

The increased incidence of LH in Japan therefore falls very obviously in line with the changed lifestyle habits in the country, the breakaway of the close physical child-mother relationships and the conversion of the "breast infant" to the "bed infant". The proof of the correctness of this view was provided by NAGURA - retrograde to a certain degree - in that he had children with LH be carried around by nurses in the old Japanese custom on their backs for one year and therefore achieved not just spontaneous positions of the femoral heads, but also an anatomical improvement of the hip relationships.

This one-time practical example of a whole people living for thousands of years isolated from external influences shows very clearly that the infant cannot always be separated from its mother without suffering damage. The view of LE DAMANY regarding the anthropological step ladder, at whose upper end is the Caucasian race with its predisposition to LH, in the middle the Asian race and at its bottom end the African American race with an extremely rare disposition to LH, has long no longer held water. However, it is repeatedly mentioned in the latest publications. That LH is virtually unknown among African, Indian, Chinese, South American and other populations who live largely naturally can only be attributed to the fact that the mothers there carry their infants and babies around with them during the day, even when working (fig. 45). If crèches, cribs and



Abb. 45 Arbeiterinnen mit ihren Kindern auf dem Rücken in einer Strickwerkstatt am Kongo

prams as well as an infant care in a European model were to be introduced there, then very likely LH would occur to an increased extent. A familial history of suffering does not necessarily have to be proof of its inheritability (NAGURA). Exogenous moments can mimic a heredity, whereby likely the combination of several factors first triggers the disease.

Various maturities of the hip joint can occur in newborns of all populations. Whether the at the time of birth dysplastic hip joint develops into LH or the maturation process catches up and normal anatomical shapes and functions form depends to a large extent on the type of infant care. If all children are carried around on the hips or backs of the mothers, then dysplasia has no meaning as a pathogenic factor of LH. The delay in the maturation process of the hip joint is compensated for by this special manner of carrying. This is particularly well illustrated by the studies from JANECEK on Korean children. In 8.76% of 114 newborns, he found pathological evidence on the hip joints in the sense of dysplasia or LH, while at an age of 14 - 20 months he could only find dysplastic disorder in 4.41% of 136 children. JANECEK draws this conclusion from this: "The custom of carrying children around on one's back means a physiological curative treatment of hip joint errors".

There is likely no doubt "that mothers carried their children around among the evolutionary ancestors of man, as is common today among anthropoid apes and many primitive peoples" (PEIPER). However, we have no accurate knowledge of when an infant and mother separated. PEIPER believes that the infant "was only recently forced into the bed against its will".

In studies in literature available to me about prehistoric cave drawings and petroglyphs in France, Spain, North Africa and Scandinavia, no representations of mother and child could be found. The lack of this representation is justified by the fact that the surviving images were for ritual purposes, primarily for 'hunting magic', and were not an expression of artistic design, as is the case at higher cultural levels of artwork.

The custom of carrying infants on one's back, hip or in devices so that their legs are bent and spread in the hip joints today prevails almost without exception among people who (roughly) live between the 40th north and 40th southern degrees of latitude. Outside of this area, the "wrapped child" is found more often, whose trunk, arms and legs are tied into one elongated package, whereby the latter are in a stretched position parallel to each other.



Initially you might think that the climate determines the type of child care. However, this cannot be correct, because especially in cold regions it would make more sense if the mother carried her child around to protect it from hypothermia with her own body heat. In addition, both types of care can be found in close proximity in the far north in similar climatic conditions: The Laplanders wrap their infants tight and tie them in a "Kumse", a cradle

made from a tree trunk (personal communication from WUSTMANN). The Eskimo mothers, on the other hand, carry them around on their backs in the hood of their outerwear (fig. 46) and later still frequently carry their children with them "piggybacking" (fig. 47).

PLOSS is also of the opinion that climatic, economic, social and other external conditions are not necessarily to be considered as causes of different forms of carrying infants. Most likely the nomadic travelling of peoples living in tents could be considered for the banishment of the child into an easy to handle and transportable package. The custom of constricting infants in a special carrying device appears to be varying degrees of ancient. This is shown by the technical perfection and rich embellishment of such equipment, as shown by the "cradle" in fig. 48 common among the North American Indian tribe of the Huron. Later, after becoming settled, such types of carrying equipment were no longer needed. This developed into the cradle and the bed and in recent times the pram while the constriction of the child has remain preserved to this day in different places.



Abb. 48 Eine bei dem nordamerikanischen Indianerstamm der Huronen gebräuchliche "Wiege"

While both types of infant care are certainly ancient, carrying the child on the mother's body is likely to be the oldest and original type of infant care. This is shown by comparison with the anthropoid apes. Depending on the climatic conditions and the cultural level of development of the people, children are only held on the mother's body with the arm (fig. 33) or with simple or artful devices. A primitive carrying strap made of wild boar or antelope skin is used, for example, by the Bambuti, a



Abb. 33 Südamerikanische Indianerin vom Kikuyu mit Kind auf der Hüfte




Abb. 49 Pygmäenfrauen vom Stamme der Bambuti am oberen Kongo tragen ihre Kinder in einem einfachen Gurt aus Wildschwein- oder Antilopenfell.



Abb. 34 Masai-Frau am Tanganjasee (Ostafrika) mit Kind auf dem Rücken



Abb. 37 Masai-Frau mit gehähtem Kinde auf dem Rücken (Ostafrika)

tribe of pygmies in the Congo (fig. 49). Frequently the child is wrapped in the mother's garments (fig. 34 and 37) or combined fabrics are artfully wrapped around the mother and child (fig. 50). According to their high cultural development, the Chinese use an exceedingly practical special carrying fabric with strings that is richly decorated with colourful ornamentation with (fig. 51 a and 51 b). It is also interesting to note that nowhere in Germany is there an area where it is still a folk custom to carry the children on the mother's back. One such island exists, for

example, in some communities in the district of Suhl. Perhaps there the mountainous landscape of the Thuringian forest helped contribute to the pram not being naturalised and therefore the old custom remain preserved of binding the child on the mother's back with a shawl (fig. 52). Since Thuringia is known as a "luxation cluster", investigations regarding the frequency of LH in communities with this old custom would be very

revealing. Such investigations on the spot exist and their results are to be published in a later work. Customs of daily life at the respective time are often shown in works of art, provided they are not strictly works of art for a certain purpose (e.g. for ritual ceremonies).



Abb. 50 Mit Hilfe eines zusammengerollten Tuches hat sich diese Mutter ihr Kind auf den Rücken gebunden (Hinterindien).



Abb. 51a Chinesin, in einem Spezialtragetuch ihr Kind auf dem Rücken tragend.



Abb. 51b Dieses Bild zeigt besonders deutlich die Zweckmäßigkeit des chinesischen Kindertragetuches, das nicht nur der Fixation des Kindes an der Mutter dient, sondern auch Rücken und Schultern des Kindes stützt, ohne seine Bewegungen stark einzuschränken.



Abb. 52 Frau mit Kind auf dem Rücken in einer Dorfgemeinde des Kreises Suhl (Thüringer Wald)

Artistic representations can therefore be viewed as historical documents, especially since an artist has to express his or her design of the idea so that it is understood by his or her contemporaries. Thus a copy of an ancient Egyptian wall painting (fig. 53) made by WILKINSON and published by PLOSS shows a group of mourners at a burial who are carrying their children with them wrapped in a cloth on the front of their bodies or on their backs. On ancient Peruvian vases, the child sits on the mother's back in a type of loop in the typical spread position (fig. 54). A Japanese wood cutting from the 18th century shows "Kintoki and his mother" (fig. 55), a special vivid display of the life of the child on the body of its mother. The child on the mother's back is also included in sculpture, such as can be seen in the "Dahomeer sacrificial dish" (fig. 54) from the Museum of Ethnology in Leipzig.

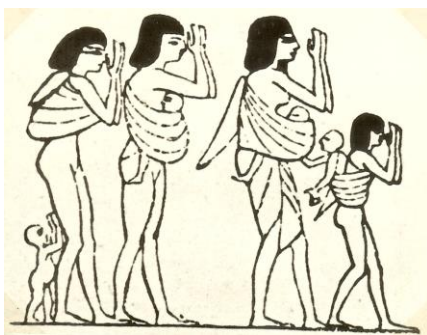


Abb. 53 Altägyptische Klageweiber mit Kindern auf ihrem Körper




Abb. 54 Alperuanische Vasen mit Darstellungen von Mutter und Kind im alltäglichen Leben



Abb. 55 Alter japanischer Holzschnitt "Kintoki und seine Mutter"

In the European region, the "wrapped child" was already shown in imagery very early on, from which it can be concluded that this type of infant care was already common at the time. Fig. 57 shows a detail from a church painting of the end of the 14th century. The child is tightly wrapped in cloths so that it cannot move. Only the head and the feet protrude out of the wrapping. The sculptures created by ANDREA DELLA ROBBIA in the 15th century at the foundling hospital in Florence are also well known, which very

clearly shows the tying of the children's body (fig. 58). Even today, for example in rural areas of Romania, the infant is wrapped with a 5-metre long wrapping cloth from the shoulders to the ankles in a traditional manner.



Abb. 57 Das "Wickelkind", der paketartig, unbeweglich eingeschmürte Säugling. Ausschnitt aus einem Bild des 14. Jahrhunderts; Meister unbekannt.



Abb. 58 ANDREA DELLA ROBbia : Wickelkind, Plastik am Fintelhaus in Florenz

The child living on the mother's body is the best prevention of LH. But the tight wrapping of the child can also be conceived as such a prophylactic measure. Even in ancient times and especially in the Middle Ages regulations about child care, the tight wrapping of the torso and the limbs was repeatedly considered to be absolutely necessary. PEIPER provides numerous source references about this. It is a known fact that sedated muscles become hypertonic due to disuse atrophy. It would be conceivable that the constraining of the limbs using ties and cloths a few days after the birth of the child was intended to prevent muscle hypertension from occurring. In this sense, a passage from the midwife book from RUEFF (1580) can be understood: "After the bath, you should rub it with ointment / It is healthy with rose oil. / At the same hour / you should spread its limbs back and forth / if it wants to stretch the same. / you may also gently guide it / because they are so delicate, x) / as you please / so that they are well formed". (cit. acc. PEIPER).

Just like many religious rules are essentially measures for maintaining health (e.g. ban on the consumption of pork because of the danger of trichinosis) and are based on an excellent observation of natural relationships, so too are many folk customs due to practical experiences. The actual relationships are usually long forgotten, while the custom lasts for centuries. In this light, the statement from SENNERT (1572 - 1637) also seems meaningful to wrap the infant after the bath so that the arms and legs cannot move so that the fragile bones are not twisted, but that the arms may be freed after 4 months, while the body (likely meant are the torso and legs!) are to be wrapped for a year (cit. acc. to PEIPER). The limbs are thus released for unrestricted activity here according to the order of neuromuscular relationships (cephalocaudal development direction). Wrapping and binding the children stretched the legs in an unphysiological manner, which may be a factor for the occurrence of LH on an insufficiently mature dysplastic hip joint. The development of another factor, that of natural muscle hypertension, is however prevented. In particular, a spasticity of the adductors cannot work "in the void" and the legs cross each other and rotate outwards, which greatly amplifies the damaging effect of the stretched legs on the cranial socket section.

The constriction of the infant does not prevent the development of LH with the same level of assuredness as carrying on the hip or back. However, it does seem suitable for preventing LH in a higher percentage of children. The abandonment of this centuries-old and perhaps even thousands of years old folk custom in the 19th and 20th century could explain the increasing frequency of LH in highly civilised countries since this time.

Conclusions for prophylaxis and the treatment of hip luxation

The realisation that the stretching of the legs and the muscular hypertension that develops soon after birth, in particular in the adductor group, are two very important mechanical and biological factors for the occurrence of LH forces us to take prophylactic measures, which primarily demand changes to today's common type of infant care. Even the common therapeutic efforts for LH need to be reviewed.

A return to the widespread wrapping and binding of children that was widespread 100 years ago would not be correct. Neither a hypertension of the muscles nor keeping the child's body away from light and air are desirable, because both lead to organic damage.

Above all the wrapping technique with swaddling clothes needs to be changed. Attention is to be paid that the legs are spread more than pushed together during wrapping. It is best to use several swaddling clothes to achieve this. The first swaddling cloth is folded together diagonally into a triangle and is placed between the legs and around the hips in the usual manner. Over this comes a four to eight-times folded square burp cloth that lies from the cross between the legs through to the navel and keeps the legs in the spread and bent position. A twice folded rectangular cloth covers this packing and reaches from the shoulder blade tip over the dam to the costal arch. The entire thing is affixed with a fourth cloth, which is folded together into approximately 6 cm wide strips, wrapped around the trunk twice and knotted on the stomach. For restless children, the tip of the third cloth can be connected to the fourth or a so-called disposable cloth is pulled over all of the swaddling clothes. The big swaddling cloth made of molleton, which encloses the infant from the thorax to the feet like a tight sack, is to be done without entirely. Instead, another carrying sack of the same material is to be used, which is fastened with shoulder straps. In such a wrapping, the infant can easily assume its own resting-sleeping position while it is impossible to cross its legs. To cover the infant, the lightest down pillows or woollen blankets are to be used, which must not be stuffed tightly between the mattress and bed so that they do not prevent the struggling movements of the legs or press these into an unnatural forced position.

A wrapping technique that is similar in principle, the "broad" wrapping, is not unknown in the treatment of hip dysplasia. However, it will require a long time of continuous education in which paediatricians, general practitioners, orthopaedic specialists and midwives and community nurses and social workers would have to be involved until such a new type of swaddling would be implemented and the thought processes leading to it would have become common knowledge of the population.

FREJKA already writes in 1941: "The most appropriate prevention (of LH) is to abandon today's manner of wrapping the child and supplementing the normal children's pillow (meant is a manner of "swaddle wrap") with an abduction pillow. In newborns with

normal abduction, a luxation may develop later over the course of the second to third month. According to this, if we want to perform the prevention in all necessary cases, then we should wrap every child in the abduction pillow without exception". ^{x)}

In 1959, J. JUDET and GIELIS suggested "putting the hips of all ^{x)} newborns in abduction until they are 4 months old. ^{x)} After this, the treatment is continued in this manner if the X-rays show anomalies that are meaningful at this age. This treatment is harmless for normal hips and useful for dysplastic hips". ^{x)}

The LORENZ position in the treatment of LH is basically nothing more than the empirically rediscovered physiological leg position of the infant, which it assumes both on the body of the mother as well as when laying and sleeping, provided it is not prevented from doing so from external circumstances (clothing, blanket). All orthopaedic aids (dressings, bandages, storage trays, spreading knickers and rails), which are used to treat LH can heal the suffering faster and more completely the more natural their position and function can mimic the legs according to the life of the child on the body of the mother. Just like the mother's body does not exert any force on the legs and hip joints of the child, the treatment must have an abducting effect without force. This is achieved with the correct with the abduction pillow according to FREJKA, the spreading knickers according to BECKER, the OVERHEAD extension, the sling according to PAVLIK and with the swing bandage developed by MITTELMEIER from the sling.

Fixation of the legs in an extreme abduction position of 90 degrees, as is often so common today, must be avoided at all costs. In such a position, the Fovea capitis femoris is outside of the socket cavum and the Lig. teres femoris inserted into it is crushed between the origin and insertion by the front edge of the socket (fig. 59). This therefore

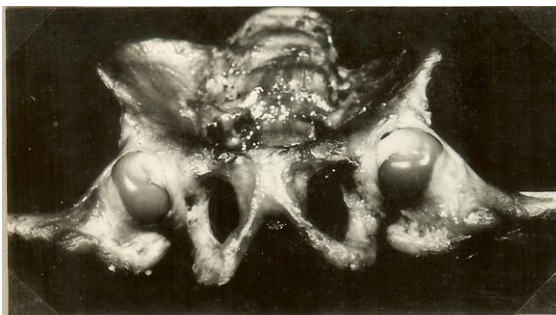

Abb. 59 In extremer LORENZ-Stellung wird das Lig. teres capitis femoris zwischen Oberschenkelkopf und vorderem Pfannenrand gequetscht.

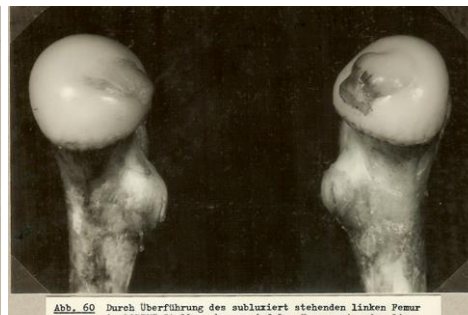

Abb. 60 Durch Überführung des subluxiert stehenden linken Femur in LORENZ-Stellung kam es infolge Kompression des Lig. teres (s. Abb. 59) zum Ödem des außerhalb des Acetabulum liegenden Bandabschnittes, zu Blutaustritten aus den Gefäßen und zur Nekrose des zentralen Bandabschnittes (vergl. auch Abb. 42).

leads to a restriction of the vessels running in the head ligament, to oedema of the section of the ligament not covered by the socket and finally to bleeding in the ligament. Fig. 60 and 42 show these changes very clearly on the left Lig. teres. What is remarkable about

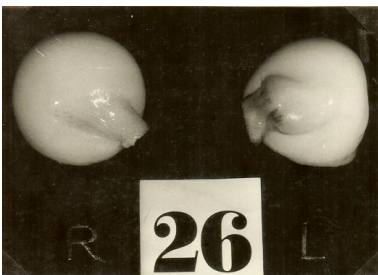

Abb. 42 Auflicht auf die Köpfe der in Abb. 41 gezeigten Femora. Der linke, subluxiert gewesene Kopf hat Dreieckform. Auf die Veränderungen am linken Lig. teres wird bei Abb. 60 näher eingegangen.

these images is that there was only a subluxation of the left hip joint on the 266-day old child, that the left leg could easily be brought into the LORENZ position under anaesthesia without overcoming the adductor contracture, and that the cast only stayed for 2 weeks until 3 days before the child died. The right leg was casted in an unforced stretched position, which is why no pathological changes can be found on the right Lig. teres femoris. An extreme abduction of the leg bent perpendicular in the hip

joint must also then be avoided when treating LH if possible under anaesthesia without coercion. The muscular hypertension occurring again after anaesthesia presses the joint bodies firmly against one another, which can lead to femoral necrosis (luxation perthes).

An improvement to child care would also be achieved by fighting the carrying of one's child on one's arm in the sitting position and with closed legs.

Already in the last century, doctors have raised their voice in warning of this method of carrying due to the risk for the spine. Carrying the child straddling the hip or in front of the body corresponds to the natural posture of the infant and small child and results in relief for the mother. If you observe children when being picked up, you can very often see that even those children who have been able to walk for a long time and who were never treated in the spread position flex and abduct their legs in the hip joints as soon as they are picked up. This appears to be a reflexive reminiscence to the original close physical mother-child relationship.



Abb. 61 Anstelle des Kinderwagens werden heute in europäischen Ländern vereinzelt Vorrichtungen benutzt, mit denen die Eltern ihre Kinder auf den Rücken mit sich herumtragen können.

Ideal for the prevention of LH would be if the modern mothers could decide to carry their children around with them as is their natural disposition. This idea is not as absurd as it may seem at first. If you read the trade and daily press attentively, then you will come across works and essays now and again that refer to damage caused to children because they have been banished to the bed as a "breast infant". The English have thus specified an apparatus that is placed in the crib to simulate the mother's heartbeat. This should make it possible to prevent neuroses in children. Fig. 61 is taken from a Viennese women's magazine and likely originates from France. The child carrying frames shown are not particularly suitable to prevent LH, but could readily be built so that they fulfil this purpose. The significant

aspect of this image, however, is that today equipment is already used in the public that is used to help mothers (and fathers) carry their children around with them. Pouches for the lying infant and the sitting small child, which are carried together by the parents, as well as baby seats to be attached in cars are already in use in many places. They should be designed so that they have a slight springy resistance to the straddled legs of the child.



Abb. 62 Amerikanisches "Huckepack-Tragetuch"

Of particular interest is fig. 62, which shows an American "piggyback wraparound carrier". The mother is to use this to carry her child around with her in the house so that no harm comes to it and it cannot injure itself. The "structure" of this shawl, however, is completely incorrect. The shawl knotted over the stomach constricts the body as was done earlier by the wasp waist corsets. In addition, it crinkles and destroys clothing, which is why no modern woman would have used the cloth for some time now. The carrying method shown is harmful to the child. The child sits over the widest part of the mother's body and must therefore must spread its legs very far, which are also twisted outward, because the cloth sometimes also includes the lower leg. This method comes approximately

close to an extreme LORENZ position. Despite these shortcomings, the image, just like fig. 61, indicates that the return of the child to the mother's body is not an unsolvable problem in today's time, but rather already clearly is heading towards a solution. This only requires overcoming the traditional bias through convincing explanations and a carrying device that is all-round satisfactory in order to complete the restoration of the natural intimate cohabitation of the child and mother and to therefore perform the best measure for preventing LH. The aim of such an education would be that all of our mothers openly carry around their children with the same ease as is a matter of course for the young Indians shown in fig. 63.



Summary

The task of this paper is to investigate whether the hip joints of children in the 1st year of life can be equated to those of older children and adults in a functional respect, under which conditions postnatal pathological changes to the hip joints may occur in the sense of LH and how their prevention can be sought.

Findings from the primitive times of man and his precursors have provided evidence that bipedalism is not a new acquisition, but rather is millions of years old. The human hip joint must therefore be viewed in form and structure as a mature design with sufficient safety coefficients.

Man belongs to the primates group, whose young are born in a state that only belongs to this mammalian group as a "physiological prematurity". After the intra-uterine foetal time, the primate child must still undergo an extra-uterine foetal time on the mother's body before it reaches the level of maturation attributed to its high organisational level as a "nest leaver". In humans, the extra-uterine foetal time lasts about one year.

The infant is ideally adapted to life on the mother's body. According to the cephalocaudal development direction of the peripheral nerve tracts, the skeleton of the upper extremities mature in infants and small children before those of the lower extremities, while in adolescence the skeletal maturation is concluded in the reverse order. Even independent forms of movement are observed on the arms and hands earlier than on the legs and feet. In a functional respect, the lower extremities are only of minor importance in newborns and young infants. It is first near the end of the 1st year of life that they mature into standing and locomotion organs.

The "hip joints" functional units in newborns and infants have several peculiarities that are to be regarded as a sensible adaptation to the intimate physical mother-child relationship. These include: the ligament-induced physiological reduced extension of the hip joints, the resting-sleeping position of the infant, the physiological hypertension of the adductor musculature and the so-called "circuitous" development of the coxal femoral end as well as the inclination of the socket inlet planes.

The natural leg position in infancy is more than a perpendicular flexion and moderate abduction. Only in this position is the impact angle of the hip joint almost a right angle, which is of crucial importance for the further maturation of the cartilage and bone tissue of the hip joint body. Dysplastic hip joints can also make up for delayed development in this leg position, regardless of the nature of the maturation deficit.

If the infant's legs are stretched against the physiological reduced inhibition, as is the case with the commonly used form of child care in highly civilised countries, then this may, with the impact of other factors, lead to the mechanical overload of the dorsal-cranial socket quadrant. This is not prepared for such an excessive strain. Mechanical causes therefore lead to biological false reactions in the differentiation of the supporting tissue, which is anatomically expressed in a sliding furrow in the rear-upper socket quadrant, a deformation of the femoral head and relative increase in the maturation delay of the hip joint body.

LH is accordingly represented as a consequence of the unnatural separation of mother and child.

Among peoples with whom the child is still a "breast infant" according to its natural characteristics, i.e. in the 1st year of life and beyond is carried riding the hip or back of the mother, LH is virtually unknown. To prevent LH, it is therefore to be sought after that all children, until learning to stand, are forced to put their legs primarily in a flexion-abduction position in the hip joints. The beginnings of such care measures already exist.

In a functional respect, the hip joints of newborns and infants cannot be equated with those of an older child and adult. According to the birth state of man, the hip joints of the infant are physiologically relatively immature.

List of literature

Alpatow, M.W.: History of Art, Volume I, Dresden 1961

Bauer, H.: Tracing the First Human, Leipzig 1956

same: A Life for the Eskimo, Leipzig 1960

Becker, F.: The Luxation Knickers, Z. Orthop. 82 (1952), 324

Same: Should the innate hip joint dislocation already be treated at infancy?, German med. Wschr. 85 (1960),

Bernbeck, R.: Pathogenesis and the healing process of hip luxation, Verh. Germ. Orthop. Ges., 37th Congress 1949

Same: On the pathology of the Luxatio coxae congenital, Virch. Arch. 320 (1951), 293

Same: On the pathological anatomy and functional pathology of hip dislocation and the luxated pelvis, Arch. Orthop. Surg. 45 (1952), 268

Same: Children's orthopaedics, Stuttgart 1952

Boebel, R.: Pathological-anatomical studies on 30 hips of newborns, summer conference of the Association of Orthopaedics of Austria, Salzburg 1961 (not yet published – light paper)

Bolk, L.: The Problem of Human Formation, Jena 1926

Brandes, G.: Buschi, from Orang Infant to Pelvic Bulge, Leipzig 1939

Braus-Elze, C.: Anatomy of a Human, Berlin-Göttingen-Heidelberg 1954

Büschelberger, H.: Hip Luxation, in: Matzen, P.F., textbook of orthopaedics, Berlin 1959

Le Demany, P.: The innate hip joint dislocation. Its causes. Its mechanism. Its anthropological meaning, Z. Orthop. Surg. 21 (1908), 129

Debrunner, H.: The treatment of innate clubfoot, Stuttgart 1958

Ebbecke, U.: Reflexes of the first days of life, Mschr. paediatrics. 99 (1951), 401

Edinger, D.: The paleoneurology at the start of a new phase, experiential, Vol. 6/7, 1950

Ehrenberg: Clin. Wschr. 337 (1949)

Elgenmark: s. W. Lenz

Faber, A.: Z. orthop. Surg. 62 (1935), 358, 374

Same: The X-ray image of the infant hip joint, verh. Germ. Orthop. Ges., 32th convention 1937

Feer, E.: Textbook on paediatrics, Jena 1958

Foerster, O.: Berlin Clinical Wschr., 1913, 1217 and 1255 (cit. acc. Peiper)

Same: The danger of conservative treatment of congenital dislocation of the hip, 6th International Orthop. Convention, Bern 1954

Same: Development of the acetabular roof for the innate hip joint luxation, contrib. orthop., 2nd conference transcript (1957), 33

Frischknecht, W.: On the early diagnosis and pathogenesis of congenital hip luxation, Swiss med. Wschr., 87 (1957), 64

Gaffrey, G.: Darwin, Creation and Development, Dresden 1959

Gaugele, K.: The so-called innate hip dislocation, in: F. Lange, textbook on orthopaedics, Jena 1928

Grimm, H.: Introduction to anthropology, Jena 1961

Goma – The Basel Gorilla Child”, Bulletin no. 1-5, Basel 1959 – 1960

Harris, L.E., Lipscomb, P.R., Hodgson, J.R.: Early diagnosis of congenital dysplasia and congenital dislocation of the hip, Journal of the American Medical Association, May 21, 1960, Vol. 173, 229

Heberer, G.: New results of the human theory of evolution, Göttingen 1951

Same: Progress in our current knowledge of ancestry history of man, natural science circular, 8 (1955), 10

Hilgenreiner, H.: On the early diagnosis and early treatment of innate hip dislocation, med. Clinic (1925), 37

Same: Rail for the early treatment of innate hip dislocation, Verh. Germ. Orthop. Ges., 23rd convention 1928

Same: 10 years of abduction rail and early treatment of innate hip dislocation, Z. orthop. 63 (1935)

Same: On the innate character of the “so-called” innate hip dislocation, Z. orthop. 65 (1936), 58

Same: On the innate dysplasia of the hip, Z. orthop. 69 (1939)

Same: Additional contribution on the teaching and treatment of innate hip dislocation, z. orthop. 70 (1940).

Hofer, H.: Advancements in the conservative treatment of the so-called innate hip luxation, contrib. orthop, 2nd conference transcript (1957), 47

Idelberger, K.: Regarding the formation of the innate malformations of the human (phenocopy and heritability), post. Orthop., 2nd conference transcript (1957), 187

Imhäuser, G.: On the pathogenesis and treatment of young hip head disconnection, Z. orthop. 88 (1956), 3

Isigkeit, E.: The innate hip dislocation, Arch. Orthop. Unf. Surg. (1928), 26

Janecek, M.: Príspevek k otázce vrozeňho vykloubení koubu kyčelního u detí v severní Koreji, Acta. Chir. Et Traum. Czech. XXIII / 1956

Jaros, M.: Etiologie vrozeňho vymkúti kyčli, Acta Chir. Orthop. Et Traum. Cech., XXVI – 5- 6 (1959)

Hoppich, G.: Anatomical and physiological peculiarities in the infant and childhood age, in: E. Feer, Textbook on paediatrics, Jena 1958

Judet, J. And Gielis, L.: Depistage et traitement des luxations congenitales de la hanche, Acta Orthop. Belgica, Fasc. 5 (1959), 440

Judet J., Judet, R., Lord, G., Roy-Camille, R. and Courtois, B.: Traitment de la luxation congenitale de la hanche de l'age de 18 mois a l'age de 4 ans, La presse Medicale 69 (1961), 161

Jurch, H. and I.: Hands as a symbol and design, Berlin 1958

Kaiser, G.: The innate hip luxation, Jena 1958

Klaatsch, H.: The coming of man and the beginnings of culture, Berlin 1936

Kleinschmidt, H.: Diet shortcomings in infants, in: E. Feer, Textbook on paediatrics, Jena 1958

Klinke, K.: The start of the psychological development in children, paediatric practice, 23 (1955), 32

Krompecher, S.: Non-published discussion contribution about the topic of “the frequency of hip luxation”, 7th conference of Med. Scien. Ges. F. Orthop. in the DDR in Leipzig (1957)

Von Lange, E.: The principles in longitudinal growth of man, yearbook for paediatrics, 57th of the 3rd series 7th volume (1903), 216

Lenz, W.: Growth: body weight and body length. Proportions. Habit. In: J. Brock, Biological data for the paediatrician, volume I, Berlin-Göttingen-Heidelberg 1954

Same: The skeletal system, in: J. Brock, Biological data for the paediatrician, volume I, Berlin-Göttingen-Heidelberg 1954

Loeffler, F.: On solving the problem of the surgical treatment of innate hip dislocation that will not set without blood

Ludloff, K.: On the pathogenesis and treatment of the innate hip joint luxation, Jena 1902

Matejcek, A. and Pesina, J.: Czech gothic painting, Prague 1950

Mattiash, H.: Maturation and development of the posture and movement apparatus, in: G. Hohmann – M. Hackenbroch – K. Lindemann, manual of orthopaedics, volume I, Stuttgart 1957

Matzen, P.F.: Textbook of orthopaedics, Berlin 1959

Mittelmaier, H.: Contribution on the functional treatment and spontaneous repositioning of innate hip luxation with spreading knickers and Pavlik bandage, Arch. Orthop. accident surgery, 52 (1961), 465

Mohing, W.: The so-called innate hip joint dislocation in: Schwalbe-Gruber, Morphology of the malformations III, 2, 977, Jena 1958

Müller, M.E.: Femoral osteotomy near the hip, Stuttgart 1957

Naef, A.: The preliminary stages of becoming a human, Jena 1933

Nagura, S.: Innate hip dislocation and folk customs, Zbl. Surg., 67 (1940), 1042

Same: On the aetiology of the innate hip dislocation, Zbl. surg., 80 (1955) 1933

Same: Influence of seasons on the frequency of innate hip dislocation, Zbl. Surg., 82 (1957), 2135

Same: On the frequency of spontaneous healing of innate hip dislocation, Zbl. Surg., 82 (1957), 1249

Same: On the treatment of innate hip dislocation, Zbl. Surg., 83 (1958), 640

Same: On the question of geographical preparation of innate hip dislocation, Arch. Orthop. accident surg., 51 (1959), 141

Same: On the question of inheriting innate hip dislocation, Zbl. Surg. 85 (1960), 2167

Nauck, E. Th.: About the “circuitous” development processes on the skeleton of the lower members of the human, Z. orthop. surg., 55 (1931), 30

Same: About the circuitous development, Morphol. Jb., 66 (1931), 65

Naumann, U-R.: The infant sleeping position, Diss. Leipzig 1958

Pauwels, F.: La sollicitation de l'extremite superieure du femur et son importance Clinique, Rapports de la III, conference internationale des maladies rhumatismales, Aix-les-Bains 1856

Same: Functional adaptation of the bone through longitudinal growth, Verh. Germ. Orthop. Ges., 45th convention 1957

Same: A new theory for the influence of mechanical stimuli on the differentiation of the supporting tissue, Z. anat. Entw.-gesch., 121 (1960), 478

Same: New guidelines for the surgical treatment of coxarthrose, verh. Germ. Orthop. ges. 48th convention 1960

Pavlik, A.: The functional treatment methods using a strap bar as a principle of conservative treatment on the innate hip joint dislocations of the infant, z. orthop, 89 (1957), 341

Peiper, A.: The crying and climbing movements of the newborn, arch. Paediatrics 147 (1953), 135

Same: The nervous system, in: J. Brock, Biological data for the paediatrician, volume II, Berlin-Göttingen-Heidelberg 1954

Same: The human infant as a nest resider and nest leaver, paediatrician practice, 23 (1955), 507

Same: Chronicle of paediatrician, Leipzig 1955

Same: The peculiarity of child brain activity, Leipzig 1956

Peiper, A and Isbert, H.: About the body position of the infant, Jb. Paediatr., 115, 3rd series (1927), 142

Peiper, A. and Thomas, H.: The principle-compliant development of upright walking, paediatrician practice, special edition, Leipzig 1953

Penners, R.: Early diagnosis and immediate treatment of innate hip luxation, arch. Orthop. surg., 47 (1955), 391

Petit: Traite des maladies des os, 2nd edit. 1, 28 (1723)

Same: On the prognosis of hip joint luxation, verh. Germ. Orthop. ges., 37th convention, 1949

Ploß, H.: The small child, Berlin 1881

Same: The child in the habits and customs of people, Leipzig 1911

Portmann, A.: From the origin of man, 4th edition, Basel 1959

Same: Zoology and the new image of man, Hamburg 1959

Same: in “Goma – The Basel Gorilla Child”, Bulletin no. 3, Basel 1960

Reich, H.: Children from around the world, Munich 1958

Rohleder, O.: The development mechanical occurrence of the so-called innate hip joint dislocation, verh. Germ. Orthop. ges., 37th convention 1949

Same: On the X-ray diagnostics of hip luxation, verh. Germ. Orthop. ges., 37th convention 1949

de Rudder, B.: On the psychopathology of childhood, human paediatrics, 99 (1951), 89

Sabata, cit. n. M. Jaros

Schebesta, P.: Bambuti, the dwarfs in the Congo, Leipzig 1932

Schede, F.: On the early diagnosis and early treatment of innate hip dislocation, Verh. Germ. Orthop. ges., 32nd convention 1937

Schede, F.: The unbloody treatment of innate hip dislocation, verh. Germ. Orthop. ges., 37th convention 1949

Schenkel, R.: in “Goma – The Basel Gorilla Child”, Bulletin no. 5, Basel 1960

Schlegel, K.F.: The innate hip luxation, in: G. Hohmann – M. Hackenbroch – K. Lindemann, Manual of orthopaedics, IVth volume, part I, Stuttgart 1961

Schnelle, H-H.: Length, scope and movement dimensions of the human body, Leipzig 1955

Stoeckel, W.: Textbook on midwifery, Jena 1945

Thurrow, I.: The infant sleeping position, Diss. Greifswald 1945

Valentin, B.: From the history of orthopaedics, in: G. Hohmann – M. Hackenbroch – K. Lindemann, Manual of orthopaedics, volume I, Stuttgart 1957

Weinert, H.: in H. Klaatsch, The coming of man and the beginnings of culture, Berlin 1936

Wolff, J.: On the question of the exogenous formation of innate malformations, *machr. Paediatrics*, 99 (1951), 136

Wustmann, E.: Xingu, Paradise without peace, Radebeul 1959

Zahradnicek, J.: Our experiences with bloody treatment of innate hip dislocation, *contribution orthop.*, 2nd conference transcript (1957), 86

Photo credit

In addition to other relevant images, the following images were kindly provided to me

From Prof. Dr. W. Ullrich, Director of the Zoo in Dresden: fig. 34, 37, 38, 39, 40, 50 and 63

From Mr. H. Graue, Friedrichroda/Thuringia: fig. 51a, 51b

From Dr. med. Mederacke, Meißen: Fig. 52 (section from 8 mm substandard film)

From Mr. E. Wustmann, Bad Schandau-Ostrau: fig. 33

I heartily thank all the gentlemen for the valuable and friendly support of my work.
Image material was taken from the following publications:

Fig. 1 from: G. Brances, Buschi, from Orang Infant to Pelvic Bulge, publishing house Quelle & Meyer, Leipzig 1939

Fig. 2, 3 from: W. Lenz, The skeletal system, in: J. Brock, Biological data for the paediatrician, Berlin-Göttingen-Heidelberg 1954

Fig. 7 from: "Goma – The Basel Gorilla Child", bulletin no. 1, Basel 1959

Fig. 8 from: U-R. Naumann, The infant sleeping position, Diss. Leipzig 1958

Fig. 29, 36 from: Braus-Elze, Anatomy of a Human, 1st volume, Berlin-Göttingen-Heidelberg 1954

Fig. 35 from: H. Reich, Children from around the world, Munich 1958

Fig. 45 from: Frankfurter Illustrated, 49th 3 (1961)

Fig. 46, 47 from: H. Bauer, A Life for the Eskimo, Leipzig 1960

Fig. 48 from: Visual Education Service, USA

Fig. 49 from: P. Schebesta, Bambuti, The dwarves from the Congo, Leipzig 1932

Fig. 53, 54 from: H. Ploß, The small child, Berlin 1881

Fig. 55 from: M.W. Alpatow, History of art, volume I, Dresden 1961

Fig. 56 from: H. Ploß, The child in the habits and customs of people, Leipzig 1911

Fig. 57 from: A. Matejcek and K. Pesina, Czech gothic painting, Prague 1950

Fig. 61 from: Voice of the Woman, Vienna 1961

Fig. 62 from: Frankfurter Illustrated, 49th 3 (1961)

All other figures were created by the author himself.